

Study of morphological subtypes of major Salivary gland tumors

Suhela Rachakonda¹, Vijaya Gattu²

¹Assistant Professor, Department of Pathology, Chalmeda Anand Rao Institute of Medical Sciences, Karimnagar.

²Assistant Professor, Department of Pathology, SVS Medical college, Yenugonda, Mahabubnagar, Telangana, India.

Address for correspondence: Dr Suhela R, Assistant Professor, Department of Pathology, Chalmeda Anand Rao Institute of Medical Sciences, Karimnagar Telangana, India.

Email: suhela24@gmail.com

ABSTRACT

Introduction: Salivary glands are the site of origin of neoplastic and non neoplastic lesions. Salivary gland tumours account for 2-6% of all the neoplasms of the Head and Neck. Major salivary gland tumors comprise a morphologically diverse group of head and neck tumors. The tumors have variations in their clinical profile related to racial and geographic differences. The tumors also have variations in the treatment types. Salivary gland tumors affect the Parotid 70% of cases followed by Submandibular glands 15%, sublingual glands 1%, minor salivary glands 5-15%.

Aims & Objectives: To find out the frequency of various morphological types of major salivary gland neoplasms. To study age, sex, duration and site distribution of different salivary gland lesions. The aim of our study was to describe the frequency of various salivary tumors and characterize them according to age, sex, anatomic location and frequency of the nature, symptoms and type of tumor. A total of 67 surgically resected specimens of salivary gland lesions were analyzed.

Materials & Methods: This is an observational study which is carried out on 67 patients having major salivary gland tumor in the department of pathology at, SVS Medical college and Hospital, from May 2012 to January 2015. Formalin fixed, paraffin embedded sections stained with hematoxylin and eosin were studied.

Results: In this study, most cases occurred at 40-50 years of age. Incidence of benign tumors was 72% while that of malignant tumors were 28% overall. Benign tumors of parotid gland were 73.3% and malignant tumors of parotid gland were 26.7%. Benign tumors of submandibular were 57% and malignant tumors of submandibular were 43%. There were no tumors from sublingual or from palate.

Conclusion: Parotid gland was the most common site of origin of both benign and malignant tumors. Pleomorphic adenoma was the most common benign salivary gland tumor and mucoepidermoid carcinoma was the most frequent malignant neoplasm. Both benign and malignant tumors were more common in males and the common age group affected was from 40-50 years.

Keywords: Salivary gland, benign, malignant, neoplasms.

INTRODUCTION

Salivary gland tumors (SGTs) are a heterogeneous group of neoplasms in the head and neck area. The tumors have complex morphologic appearance and different clinical behavior, which make their diagnosis difficult^{1,2}.

These tumors are rare lesions; represent less than 1% of all tumors and 3-6% of all head and neck neoplasms^{3,4}. The annual incidence of salivary gland cancers ranges from 0.5 to 2 per 100,000 in different parts of the world⁵.

The distribution based on gender for salivary gland cancers is equal, and the majority of the cases arise in the fifth decade⁶. The majority of these neoplasms are benign and only 20% are malignant^{7,8}.

Among benign salivary gland neoplasm, 80% contributes pleomorphic adenoma, 10% Warthin's tumor and 10% others. On the other hand, malignant neoplasm of salivary gland comprises mucoepidermoid carcinoma (35%), carcinoma ex pleomorphic adenoma (20%) and acinic cell carcinoma (10-25%)⁹.

Most benign neoplasm of major salivary gland manifest insidiously, that is growing slowly over a long period of time without causing any other symptoms, whereas malignant neoplasm may present with rapidly enlarging swelling, pain, nerve palsy, invasion into skin and neck nodes. Facial nerve paralysis is a presenting feature appears approximately one third of patients of parotid malignancy¹⁰.

Pleomorphic adenoma is the most common salivary gland neoplasm; grossly the tumor ranges from few millimeters to centimeters with well encapsulation. Cut surface may be fleshy, rubbery or glistening. On microscopic examination the tumor shows epithelial component which may be arranged in tubules, cysts, ribbons, solid sheets. [Figure 1] The cells may be columnar, cuboidal or flat. Stroma may take the form of chondroid, myxoid, chondromyxoid, hyaline and very rarely osseous or adipose tissue. We in our present study got one case with osseous, chondroid and myxoid differentiation. [Figure 2].

Warthin's tumor is also known as papillary cyst adenoma lymphomatosum is second most common tumor of salivary gland. It is more common in men compared to women with highest peak in incidence between 6th to 7th decades. Grossly tumor is well circumscribed, spherical to ovoid mass, cut surface of the tumor show variable sizes cystic spaces.[Figure 3]

Histological examination epithelial component often form papillary projections into the cystic structure. Epithelium contains two layers luminal layer is oncocytic columnar cells which are supported by basal cells. The lymphoid stroma closely resembles a normal lymph node, with lymphoid follicles and follicular centers.[Figure 4].

Adenoid cystic carcinoma is previously known as cylindroma commonly occur in 4th to 6th decades of life with female predominance. On histological examination three patterns are noted- cribriform, tubular and solid.[Figure 5].

Mucoepidermoid carcinoma most commonly occurs in parotid gland and minor salivary gland. Women are affected slightly higher compared to men with peak age 5th decades. On histological examination three types of cell are found- epidermoid cell, mucus secreting cells and intermediate cells. Individual cell keratinization and intercellular bridge are seen in epidermoid cell.[Figure 6].

MATERIALS AND METHODS

A total of 67 patients of both sexes were taken. Neoplastic lesion was diagnosed by detailed history, physical examination, USG , Cytological and histopathological examination and relevant laboratory investigations. All neoplastic swellings confirmed by FNAC were included and autoimmune, inflammatory, granulomatous swelling involving salivary glands and neoplasm involving minor salivary glands and which did not correlate with FNAC were excluded.

RESULTS

In this series 89.5% patients had parotid, 10.5% had submandibular and none had sublingual major salivary tumor. Highest incidence of tumors were found in 4th -5th decade of life and next common age incidence have been noted in 3rd decade. Male :female ratio in benign tumors is 2.03:1. (67%:33%). Male:female ratio in malignancies is 1.1:1.(53%:47%).

Table 1: Incidence based on gender:

S.No.	Gender	Frequency	Percentage
1	Male	42	63.00%
2	Female	25	37.00%

Table 2: Sex distribution in benign and malignant tumors in various studies.

Studies	Benign(M:F)	Malignant(M:F)
Ahmed et al ¹⁷	1.1:1	1.1:1
Edda et al ¹⁸	1:1.4	1.1:1
Ankur et al ²²	1.9:1	1:3.3
Akther et al ¹⁰	1.5:1	1.2:1
Our study	2.03:1	1.1:1

Table 3: Distribution according to site of tumor:

S.No.	SITE OF TUMOR	Frequency	Percentage
1	PAROTID	60	89.50%
2	SUBMANDIBULAR	7	10.50%
3	SUBLINGUAL	0	0.00%

Table 4: Distribution of parotid and submandibular and other lesions in various studies

Studies	Parotid	Submandibular	others
Edda et al ¹⁸	34%	33%	33%
Ahmed et al ¹⁷	70%	18%	12%
Tanaka et al	75%	25%	-
Our study	89.5	10.5	-

Table 5: Distribution based on presenting symptoms

S.No	Symptom	Frequency	Percentage
1	Swelling	65	97.00%
2	Pain	16	24.00%
3	Swelling and Pain	15	22.00%
4	Facial Nerve Paralysis	10	15.00%

Table 6: Distribution based on Histopathological distribution of patients.

	PAROTID GLAND		SUB MANDIBULAR GLAND	
Benign	Pleomorphic adenoma	30 (68%)	Pleomorphic adenoma	04 (100%)
	Warthins tumor	9 (20%)		
	Basal cell adenoma	3 (07%)		
	Oncocytoma	2 (05%)		
Malignant	Mucoepidermoid carcinoma	7 (44%)	Mucoepidermoid carcinoma	02 (67%)
	Adenoid cystic carcinoma	4 (25%)		
	Acinic cell carcinoma	3 (18%)	Adenoid cystic carcinoma	01 (33%)
	Carcinoma ex pleomorphic tumor	2 (13%)		

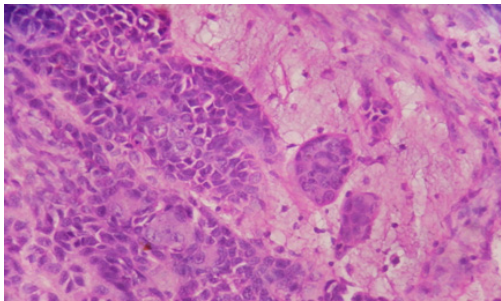


Figure 1: H&E showing pleomorphic adenoma 40X view

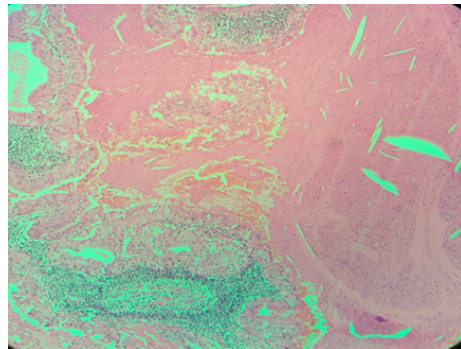


Figure 4: H&E showing oncocytic cells and lymphoid follicles 10X view (Warthins tumour)

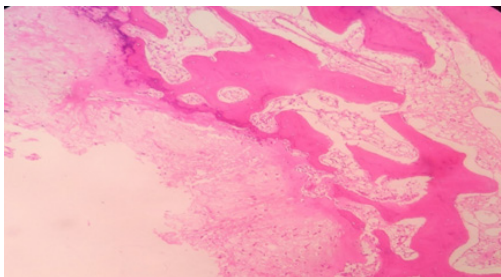


Figure 2: H&E showing osseous, chondroid and myxoid differentiation 10X view

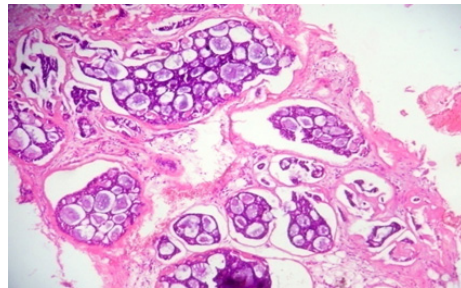


Figure 5: H&E image showing adenoid cystic carcinoma 10X view

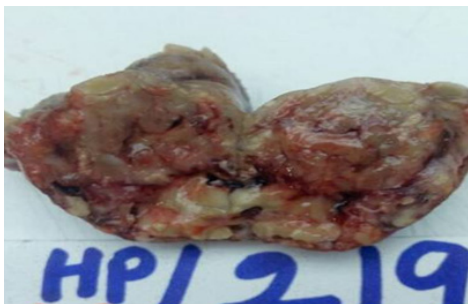

Figure 3: Gross image showing Warthins tumor

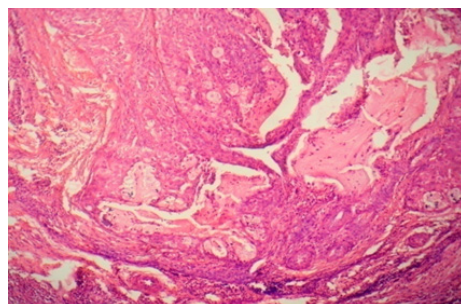


Figure 6: H&E image showing muco-epidermoid carcinoma 10X view

DISCUSSION

Salivary glands are divided into major and minor salivary glands. Salivary glands tumors are relatively uncommon, they can be presented as inflammatory lesions, developmental defects and neoplasms but their clinical presentation, morphologic differentiation and relatively unpredictable prognosis tend to attract much of medical interest¹². Neoplasm of salivary gland may occur at any age. In this study highest number of patients was in the 4th to 5th decade which was 19 patients (28%) and comparable with the findings of Dr. shazia et al¹³. High male to female ratio has been reported in several other studies¹⁴⁻¹⁶.

Pleomorphic adenoma (PA) undoubtedly is the most common salivary gland tumor (SGTs). As, similar to the present study, all researchers from other parts of world have noticed that this neoplasm stands for 40.4-89.9%¹⁹⁻²². In our study, among the parotid malignancy, 44% were mucoepidermoid carcinoma and 13% were carcinoma in pleomorphic adenoma, consistent with the study of Archana shetty et al²³ in which Muco epidermoid carcinoma occurred more followed by adenoid cystic carcinomas. Most of the patients of malignant tumors admitted in the hospital at stage III which is consistent with the findings of Jones et al²⁴.

CONCLUSION

From this study we want to conclude that parotid gland was the most common site of origin of both benign and malignant tumours. Plemorphic adenoma was the most common benign salivary gland tumour followed by warthins tumor and mucoepidermoid carcinoma was the most frequent malignant neoplasm followed by adenoid cystic carcinoma. Here we present common tumors with their histopathological images which are important in the final diagnosis. This information could help physician, surgeons and pathologists for more accurate diagnosis, management and early treatment reducing the occurrence of complications in any higher centre.

REFERENCES

1. Ansari M. Salivary gland tumors in an Iranian population: a retrospective study of 130 cases. *J Oral Maxillofac Surg.* 2007; 65:2187-94.
2. Jones AV, Craig GT, Speight PM, et al. The range and demographics of salivary gland tumors diagnosed in a UK population. *Oral Oncol* 2008;44, 407-17.
3. Ethunandan M, Davies B, Pratt CA, Puxeddu R, Brennan PA. Primary epithelial submandibular salivary gland tumors-Review of management in a district general hospital setting. *Oral Oncol* 2009;45:173-6.
4. Pons-Vicente O, Almendros-Marqués N, Berini-Aytés L, Gay Escoda C. Minor salivary gland tumors: A clinicopathological study of 18 cases. *Med Oral Pathol Oral Cir Bucal* 2008;13:E582-8.
5. Parkin DM, Ferlay J, Curado MP et al. Fifty years of cancer incidence: CI5 I-IX. *International Journal of Cancer* 2010; 127(12):2918-27.
6. Licitra L, Grandi C, Prott FJ, Schornagel JH, Bruzzi P, Molinari R. Major and minor salivary glands tumours. *Critical Reviews in Oncology/Hematology* 2003;45(2):215-25.
7. Arshad AR. Parotid swellings: report of 110 consecutive cases. *Medical Journal of Malaysia* 1998;53(4):417-22.
8. Loyola AM, De Araujo VC, De Sousa SOM, De Araujo NS. Minor salivary gland tumours. A retrospective study of 164 cases in a Brazilian population. *European Journal of Cancer* 1995;31(3):197-201.
9. Izzo L, Casullo A, Caputo M, Costi U. Space occupying lesion of parotid gland comparative diagnostic imaging and pathological analysis of Echo colour/power Doppler and magnetic Resonance Imaging. *Acta Otorhinolaryngol Ital* 2006;26(3): 147-53 .
10. Akhter J, Hirachand S, Lakhey M. Role of FNAC in the diagnosis of salivary gland swellings : Kathmandu University Medical Journal 2008; Vol.6(2): 204-208.
11. Barnes LB, Eveson JW, Reichart P, Sidransky D. editors. *Pathology and Genetics of Head and Neck Tumors*. Lyon: IARC Press; 2005.
12. Huvos AG. *Salivary glands* In: Sternberg SS(ed). *Diagnostic surgical pathology*. 2nd ed. Philadelphia; Lippincott-Raven, 1994, p.813.
13. *Histopathological Spectrum of Salivary Gland Tumors: A 10 Year Experience* Dr. Shazia Bashir, et Scholars Journal of Applied Medical Sciences (SJAMS) Sch. J. App. Med. Sci., 2013; 1(6):1070-1074.
14. Ahmad J, Hashmi MA, Naveed IA, et al. Spectrwn of malignancies, in Faisalabad., 1986-1990. *Pak. J. Pathol.*, 1992,3:103-10.
15. Jafarey NA. Frequency of malignant tumors in seven centres of Pakistan. *Pakistan Medical Research Council Cancer Study Group. J. Pak. Med. Assoc.*, 1977;27:335-39.
16. Khan SM, Gillani J, Nasreen S, et al. Cancer in North-West Pakistan. *Pak. J. Med. Res.*, 1996;35:167-69.
17. Ahmd et al. Clinicopathological study of primary salivary gland tumors in Kashmir. 2002; 4(9):231-233.

18. Edda A M Vuhahula. Salivary gland tumors in Uganda: clinical pathological study. African health sciences 2004; 1(4): 15-23.
19. Vazirinia E A. Maor Salivary gland neoplasms: clinical study. Annals of African Medicine 2005; 4:19-23.
20. Li LJ, Li Y, Wen YM, et al. Clinical analysis of salivary gland tumor in West China in past 50 years. Oral Oncol, 2008;44:187-92.
21. Atarbashi-Moghadam S, Atarbashi-Moghadam F, Dadfar M. Epithelial salivary gland tumors in Ahvaz, Southwest of Iran. J Dent Res Dent Clin Dent Prospect 2010; 4:120-3.
22. Ankut et al. Histopathological spectrum of salivary lesions. International Journal of Scientific Research 2014; 3(1): 22-29.
23. Archana Shetty, Geethamani V. Spectrum of Major Salivary Gland Tumours: Clinicopathologic Study. Sch. J. App. Med. Sciences 2014; 2(3C): 1088-1090.
24. Jones AS. Malignant tumours of salivary gland. Michael Gleeson ed. Scott-Brown's Otorhinolaryngology, Head-Neck volume-2. 7th ed Hodder Arnoal, 2008; 190:2504-06.

How to cite this article : Suhela R, Vijaya Gattu. Study of morphological subtypes of major Salivary gland tumors. Perspectives in Medical Research 2017;5(3):24-28.

Sources of Support: Nil, Conflict of interest: None declared