



Left sided ablation for Atrioventricular Nodal Re-entrant Tachycardia: Frequency, Characteristics and Outcomes

Kumar Narayanan^{*}, Mohammed Omer, Mohammed Arif, Papani Sridhar, Nitin Annarapu, Shivaprasad Naidu, Pankaj Jariwala, Narasaraju Kavalipati, Mukharjee Madivada, Ramagiri Balaji, Premchand M, Sharath Reddy A, Anil Krishna G, Padmakumar EA

Department of Cardiology, Medicover Hospitals, Hyderabad, India

ARTICLE INFO

Article history:

Received 15 August 2020
Received in revised form
4 October 2020
Accepted 21 October 2020
Available online 28 October 2020

Keywords:

AVNRT
Ablation
Left-sided
Mitral
Trans-septal

ABSTRACT

Background: Left-sided ablation, targeting left inferior AV nodal extensions, is thought to be necessary for success in a small proportion of atrioventricular nodal re-entrant tachycardia (AVNRT) ablations; however Indian data are scarce in this regard.

Methods: Consecutive cases of AVNRT undergoing slow pathway ablation in a single centre over an 18-month period were retrospectively analyzed. Left-sided ablation at the posteroseptal mitral annulus was performed if right-sided ablation failed to abolish AVNRT.

Results: From January 2017 to June 2018, out of 215 consecutive supraventricular tachycardia (SVT) cases, 154 (71.6%) were AVNRT (47.1 ± 13.1 years, 46.1% male). Trans-septal ablation was required in 5 (3.2%) cases (mean age 48.8 ± 9.4 years; 4 female, 1 male); all with typical (slow-fast) form of AVNRT. Compared with cases needing only right-sided ablation, radiofrequency time (50.8 ± 16.9 vs. 9.9 ± 8.5 min; $p = 0.005$) and procedure time (166.0 ± 35.0 vs 79.6 ± 35.9 min; $p = 0.004$) were significantly longer for trans-septal cases, while baseline intervals and tachycardia cycle length were not significantly different. Junctional ectopy was seen in only 2 of the 5 cases during left-sided ablation, but acute success (non-inducibility) was obtained in 3 cases. There were no instances of AV block. Over mean follow-up of 12.2 ± 4.0 months, clinical recurrence of AVNRT occurred in one case, while others remained arrhythmia-free without medication.

Conclusion: Left-sided ablation was required in a small proportion of AVNRT ablations. Trans-septal approach targeting the posteroseptal mitral annulus was safe and yielded good mid-term clinical success. Copyright © 2020, Indian Heart Rhythm Society. Production and hosting by Elsevier B.V. This is an open access article under the CC BY-NC-ND license (<http://creativecommons.org/licenses/by-nc-nd/4.0/>).

1. Introduction

Atrioventricular nodal re-entrant tachycardia (AVNRT) is the commonest supraventricular tachycardia (SVT) encountered in clinical practice [1]. Catheter ablation is the treatment of choice for AVNRT, especially if it is drug refractory, considering the high success rates and low risk of complications [2]. AVNRT is postulated to arise due to the so called dual AV node physiology, wherein, two possible pathways for conduction, namely the fast pathway and slow pathway exist in the AV node, with different conduction velocities and refractory periods, thereby setting up conditions for re-

entry [3].

Radiofrequency ablation (RFA) of the slow pathway has been established as the safest and most effective means of successfully eliminating AVNRT [4,5]. Slow pathway RFA can be achieved successfully in most cases by ablation at the inferior aspect of the triangle of Koch, considered to be the location of the right inferior nodal extension [6]. However, in a small proportion of cases, elimination of AVNRT can prove very difficult despite conventional ablation at the inferior Koch's triangle as well as higher up in the right mid-septal region, which is also additionally fraught with a greater risk of AV block. It has been proposed that left sided inferior nodal extensions could constitute the critical slow pathway in some cases and may need to be targeted to achieve success. Both ablation inside the coronary sinus (CS), a few millimetres from the ostium, and in the left posteroseptal mitral annulus have been described to ablate such leftward AV nodal extensions [7–9]. Data regarding left

^{*} Corresponding author. Department of Cardiology/Electrophysiology, Medicover Hospitals, Hitec City, Hyderabad, India.

E-mail address: kumardoc96@yahoo.com (K. Narayanan).

Peer review under responsibility of Indian Heart Rhythm Society.

sided ablations for AVNRT have been mainly derived from western studies, with relatively limited data from Asian populations.

We performed a retrospective study of consecutive cases of AVNRT undergoing ablation from a single centre in South India, to assess the frequency of left sided ablation, clinical characteristics, success rates and follow-up.

2. Methods

2.1. Study population

This was a retrospective analysis carried out in a single tertiary care centre in South India. Our centre has a dedicated electrophysiology service and performs around 150 to 175 SVT ablations every year, most of which is AVNRT. Consecutive cases of AVNRT undergoing catheter ablation over an 18-month period (January 2017 to June 2018) were analyzed. All patients had symptomatic AVNRT. Indications for ablation were recurrent symptoms despite medications, intolerance to medications or patient preference for ablation rather than taking regular medications. Only patients undergoing a first ablation procedure were included in this study; subjects undergoing repeat procedures were not included.

2.2. Data collected

Demographic and clinical characteristics including age, sex and presence of cardiovascular risk factors such as diabetes, hypertension etc. were obtained from medical records. Information on LV function and presence of any structural heart disease was obtained from echocardiogram report. Coronary artery disease (CAD) was defined as > 50% stenosis in an epicardial coronary artery in angiogram, past history of CAD, myocardial infarction (MI) or percutaneous coronary angioplasty. Renal dysfunction was defined as a creatinine value ≥ 1.5 mg/dL.

2.3. Ablation procedure

Catheter ablation was carried out using a standard protocol in the cardiac catheterization laboratory, under local anaesthesia using the WorkMate™ electrophysiology system (Abbott Labs, St Paul, USA). Rate control medications, such as beta blockers and calcium channel blockers were stopped at least 48 hours prior to procedure. Right femoral transvenous access was used for catheter placement universally. The standard procedure used three catheters, namely a decapolar catheter in the coronary sinus (CS), a quadripolar catheter in the His location and an ablation catheter, which was also used as a right ventricular (RV) catheter during the initial electrophysiology (EP) study. Diagnoses of typical (slow-fast) and atypical (slow-slow) AVNRT were confirmed using standard electrophysiologic manoeuvres as per definitions described in literature [10]. Radiofrequency (RF) energy was used for ablation in all cases. The slow pathway was targeted for ablation at the inferior Kochs triangle using an anatomical approach, under fluoroscopic guidance, as has been described [6]. Non-irrigated ablation was used; usual RF settings were 35–40 Watts power and 55–60 °C, which was changed as per operator discretion in individual cases if required. Endpoints for ablation included non-inducibility of AVNRT as well as significant modification of slow pathway conduction, defined as not more than one AV nodal echo on atrial programmed electrical stimulation (PES) [11]. Robust attempts at re-induction of AVNRT were performed in all cases, including using isoprenaline infusion, atrial burst pacing and at least two atrial extrastimuli on PES. Procedural details of the AVNRT ablation were collated from the procedure notes as well as stored data in the EP system, and included total procedure time, RF time and use of long sheath for

stability.

2.4. Left sided (trans-septal) ablation

Left sided (trans-septal) ablation was performed, if AVNRT (sustained or non-sustained) was re-inducible despite extensive right sided ablation. This generally included ablation first at the standard slow pathway location at the inferior triangle of Koch, followed by cautious ablation at relatively higher level in the mid-septal region, and finally low power ablation (20–25 W) inside the CS. CS ablation was usually within 1 cm of the CS ostium. Coronary angiography was not systematically performed prior to CS ablation; however only low power (<25 W), non-irrigated ablation was used and ablation was limited to maximum 30 seconds at a time, while monitoring the ECG. Slow junctional rhythm was aimed at during ablation, with 1:1 VA conduction in every beat. Ablation was promptly terminated on occurrence of either fast junctional rhythm or VA block for a single beat. If AVNRT was re-inducible despite all the above steps, trans-septal access was obtained in standard fashion using a SLO long sheath (Abbott, USA) and Brockenborough needle (Medtronic, USA). The posteroseptal mitral annulus was targeted for ablation under fluoroscopic guidance, aiming for a small atrial and large ventricular signal, without any left sided His signal. Representative RAO and LAO fluoroscopic views from a successful case with junctional beats during left sided ablation are shown in Fig. 1 (views from other patients included as supplementary figures). Left sided ablation was started at the lowest level possible, below the CS ostium level, with a small A and large V signal. Representative electrograms at the site of ablation in two cases, where junctional rhythm was obtained, are shown in Fig. 2. In case of lack of success, the ablation catheter was moved cautiously higher, up to a maximum level which could be said to correspond to a right sided “mid septal” level. Similar safety parameters were followed, as for right sided ablation. Anticoagulation with heparin at 100 units/Kg body weight was used in case of left sided ablation.

2.5. Follow-up

Anti-arrhythmic and rate control medications were discontinued post procedure in all patients except two. All patients were advised systematic follow-up at 2 weeks, 3 months, 6 months and one year, as well as interim visits if they had any symptoms. All patients were instructed to promptly obtain a 12-lead ECG at the nearest available centre in case of any suspicious symptoms. The importance of obtaining an ECG during symptoms was stressed, in order to pick up any recurrences.

2.6. Statistical analysis

Continuous variables were expressed as mean and standard deviation, categorical variables were expressed as numbers and percentages. Comparisons were performed using *t*-test for continuous variables and chi-square test for categorical variables. *P* value ≤ 0.05 was considered significant. Statistical analysis was performed using Microsoft Excel (Microsoft corp., USA).

3. Results

From January 2017 to June 2018, out of a total of 215 consecutive cases of SVT, 154 (71.6%) were AVNRT. Baseline demographic and clinical characteristics of the AVNRT cases are listed in Table 1. The mean age of the patients was 47.1 ± 13.1 years and majority were females. Concomitant coronary artery disease was seen in 10.4% of cases and left ventricular systolic function was normal, except in

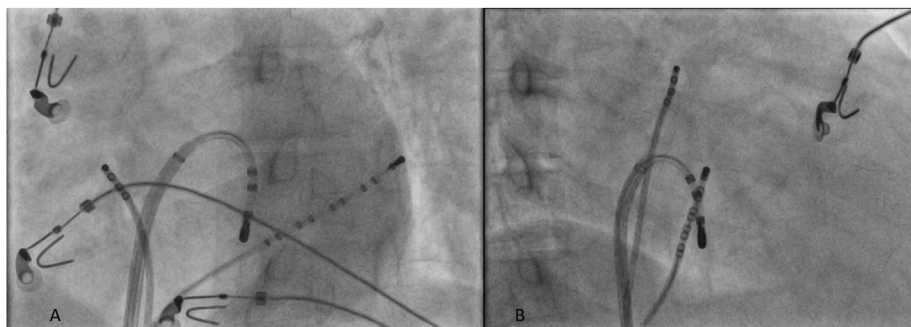


Fig. 1. Left anterior oblique (LAO; panel A) and Right anterior oblique (RAO; panel B) views showing the usual site for left sided trans-septal ablation at the posteroseptal mitral annulus.

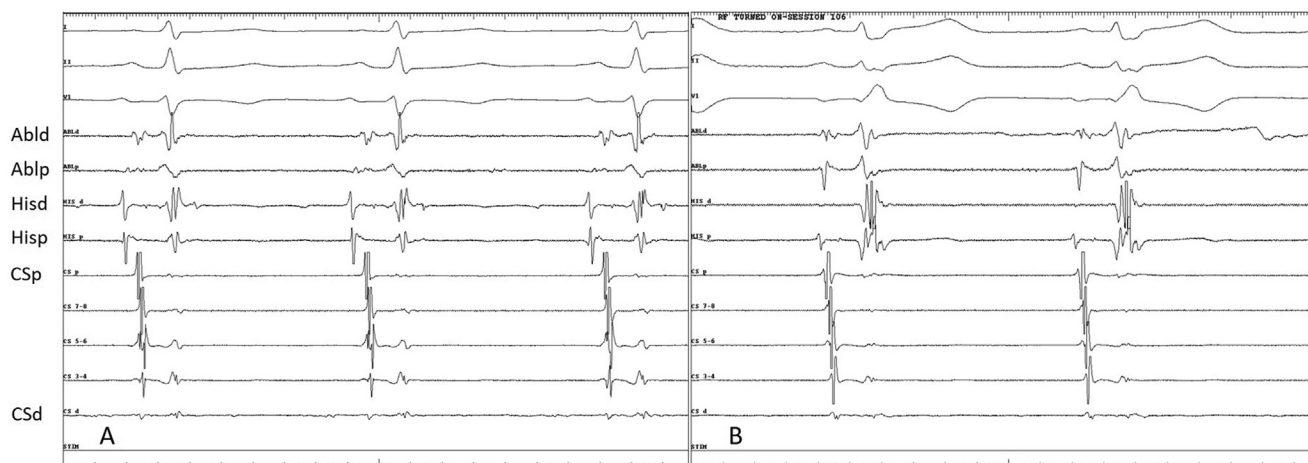


Fig. 2. Panels A and B showing representative electrograms from two cases at sites where junctional beats were obtained in left sided ablation. (Abl - Ablation catheter signals, His- His catheter signals, CS- Coronary sinus signals; d-distal; p-proximal).

Table 1
Demographic, Clinical and Procedural Details of Patients undergoing AVNRT ablation (n = 154).

Age (years)	47.1 ± 13.1
Male, n (%)	71 (46.1)
Diabetes, n (%)	29 (18.8)
Hypertension, n (%)	42 (27.3)
Coronary artery disease n (%)	16 (10.4)
LV Systolic Dysfunction n (%)	2 (1.2)
Renal Disease, n (%)	13 (8.4)
Use of Long Sheath, n (%)	10 (6.5)
Mean Procedure time	82.9 ± 39.5 min
Mean RF Duration	11.4 ± 11.8 min
Mean RF Power	28.1 ± 6.2 W
Mean RF Temperature	48.4 ± 6.6° Celsius
Ablation inside CS, n (%)	18 (11.7)

LV- Left Ventricular; RF- Radiofrequency, CS- Coronary sinus.

two cases. There was no structural heart disease, except in one case who had a repaired sub-pulmonic ventricular septal defect.

Pre procedure medications were beta blockers and/or calcium channel blockers in all cases and amiodarone in one case. Almost all patients had the typical (slow-fast) form of AVNRT, except one who had only atypical (slow-slow) AVNRT and two others, who had both forms (typical and atypical) of AVNRT inducible.

Mean total procedure time was 82.9 ± 39.5 min, with mean RF duration of 11.4 ± 11.8 min. Among the cases in which only right sided ablation was performed, a long sheath was needed for

stability in five cases; either an SLO or Agilis sheath (Abbott, USA) was used. Three dimensional mapping systems or irrigated ablation were not used in any case. In addition to ablation in the Koch's triangle, overall 18 of the 154 patients (11.7%) had additional ablation within the coronary sinus. This helped acutely abolish AVNRT in all except the five cases who required additional left sided ablation as detailed below.

3.1. Left sided ablation

Left sided (trans-septal) ablation was performed in 5 out of 154 cases (3.2%; 95% confidence interval 1.1–7.4%) as a result of failure of extensive right sided ablation (including within the coronary sinus) to eliminate the arrhythmia. All the 5 cases (mean age 48.8 ± 9.4 years; 4 female, 1 male) had the typical (slow-fast) form of AVNRT. The posteroseptal mitral annulus region was targeted under fluoroscopic guidance as already described in the methods (Fig. 1), aiming for slow junctional rhythm. Compared to only right sided ablation, both the average RF time (50.8 ± 16.9 vs. 9.9 ± 8.5 min; p = 0.005) and procedure time (166.0 ± 35.0 vs. 79.6 ± 35.9 min; p = 0.004) were significantly longer (Table 2). This was mainly due to prolonged attempts at right sided ablation, including, in some cases, performing linear ablation line from CS ostium to tricuspid annulus, before finally going trans-septal. Electrophysiologic characteristics, including basal sinus cycle length, AH interval, HV interval and tachycardia cycle length were not significantly different between the two groups (Table 2).

Table 2
Comparison of Demographic/Procedural Characteristics between Right sided and Left sided ablation.

	Right Sided Ablation Only (n = 149)	Right plus Left sided Ablation (n = 5)	P value
Age (years)	47.0 ± 13.2	48.8 ± 9.4	0.70
Female, n (%)	79 (53.0)	4 (80.0)	0.24
Sinus cycle length (ms)	740.7 ± 140.5	757.0 ± 121.7	0.78
AH Interval (ms)	71.7 ± 16.8	78.6 ± 16.4	0.40
HV Interval (ms)	44.2 ± 8.6	45.2 ± 7.6	0.80
Tachycardia Cycle length (ms)	321.2 ± 42.1	302.5 ± 54.4	0.54
RF time (minutes)	9.9 ± 8.5	50.8 ± 16.9	0.005
Procedure time (minutes)	79.6 ± 35.9	166.0 ± 35.0	0.004
RF Power (Watts)	29.1 ± 6.2	27.2 ± 7.3	0.59

AH- Atrium-to-His interval, HV- His-to-Ventricle interval, RF- Radiofrequency.

Junctional ectopy was obtained in only 2 of the 5 cases during left sided radiofrequency application. However, AVNRT was rendered completely non-inducible in 3 out of the 5 cases after left sided ablation, despite aggressive re-induction testing. In the remaining two cases, non-sustained AVNRT (5–6 beats) was inducible on high dose isoproterenol in one case, while in the other, sustained tachycardia was inducible on isoproterenol despite left sided ablation and was deemed an acute failure. In the former case with non-sustained AVNRT, induction of the arrhythmia only on programmed atrial stimulation with double atrial extrastimuli and consistent initiation of arrhythmia with abrupt AH prolongation, both suggested true AVNRT rather than accelerated junctional rhythm due to isoproterenol.

There was no acute occurrence of AV block in any of the cases. There were no instances of coronary arterial complications related to CS ablation.

3.2. Follow-up

Mean duration of follow-up was 12.2 ± 4.0 months. All patients completed at least 2 follow-up visits. There was no clinical, symptomatic recurrence of AVNRT, except in the one case, which was an acute procedural failure, despite left sided ablation. This patient was restarted on metoprolol and had 2 clinical recurrences till last follow-up. All other patients remained off any anti-arrhythmic medications. There were no delayed instances of AV block or any other adverse events noted at follow-up.

4. Discussion

In this study of consecutive patients with AVNRT undergoing ablation, 3.2% of patients needed left sided ablation at the septal mitral annulus due to failure of right sided ablation, including within the CS to abolish the arrhythmia. Although junctional rhythm was not obtained in all patients undergoing left sided ablation, acute success could still be achieved in 3 out of 5 cases and midterm clinical success in 4 of 5 cases. Cases needing left sided ablation had longer RF and procedure times, mainly due to prolonged attempt on the right side. Electrophysiologic characteristics including AH, HV intervals and tachycardia cycle length did not significantly differ between the two groups.

The observation that some cases of AV junction ablation require left sided ablation for success, led operators to initially attempt left sided ablation for AVNRT at the septal mitral annulus. This strategy was shown to be successful either by the retrograde aortic or trans-septal approach in small series initially [12] [8]. Subsequently, the concept of left sided inferior nodal extensions warranting left sided ablation in a proportion of AVNRT cases has been confirmed in larger studies. In a series of 221 cases, Katritsis et al. reported 1.8% of patients requiring left sided ablation with good success and low recurrence rates [7]. In another study of 587 patients with typical

AVNRT, left sided ablation, either in posteroseptal or mid septal mitral annulus, was required in 1.5% of cases where extensive right sided ablation had failed, with left sided ablation succeeding in all but one case. The tachycardia cycle length was noted to be longer in patients needing left sided ablation, with no other significant differences in clinical or electrophysiologic characteristics [13]. A series comparing typical and atypical variants of AVNRT, reported need for left septal ablation in 2.7% of atypical AVNRT, but not in typical AVNRT [14]. It is noteworthy that all cases needing left sided ablation in the present series had typical form of AVNRT.

Junctional beats during ablation were obtained in only 2 out of the 4 cases with clinical success in left sided ablation in the present study. The available literature suggests that occurrence of junctional rhythm, while encountered in most cases, is not universal. In a recent large series involving >1000 patients, junctional rhythm during AVNRT ablation was noted in about 96% of cases and junctional rhythm was not a predictor of arrhythmia recurrence. Junctional rhythm is a sensitive but not specific predictor of ablation success [15]. The lower proportion of junctional rhythm noted in our left sided ablations may be related to the limited number of patients studied. Further studies with greater number of patients will help clarify the optimal end points for success in left sided AVNRT ablation.

Ablation at the mitral annulus for AVNRT has been mostly described from Western literature, with scarce reports from the Asian region. Ito et al. described a trans-aortic approach to left sided ablation for AVNRT [16]. Other studies, although detailing the concept of left nodal extensions participating in AVNRT, have described only ablation within the CS to successfully eliminate such extensions. Nam et al. described eccentric CS activation pattern (earliest activation 10–20 mm inside CS), as denoting left atrio-nodal connections in AVNRT, with ablation within the CS being needed in a minority to achieve success [17]. Another Japanese study involving only atypical AVNRT, similarly denoted eccentric CS activation and need for ablation within the CS to eliminate such “left variant” AVNRTs [18]. Using careful analysis with CS venography, eccentric CS activation in AVNRT has been described in almost 7% of AVNRT; however presence of such activation does not necessarily predict the need for left sided or CS ablation for success. Left sided inputs have been suggested to be more common in females and in atypical variants of AVNRT [19]. Contrarily, no eccentric CS activation was noted in our series of patients; although in the absence of systematic CS venography, some may have been missed.

It is increasingly recognised that the AVNRT circuit is not strictly confined to the compact AV node, but involves adjoining atrial tissue as well. The existence of both right and left sided posterior nodal extensions has been shown anatomically [20,21]. Using cellular action potential recordings as well as immunohistochemistry, AV nodal-like cells have been demonstrated adjacent to both tricuspid and mitral annuli and thought to form the substrate for

slow pathway conduction [22]. Careful intra-cardiac recordings have shown earlier activation on the left side of the atrial septum during retrograde slow pathway conduction, as well as shorter stimulus to His intervals when pacing from the left infero-paraseptal area as compared to the right. However, both of these were shown to be abolished by conventional right sided slow pathway ablation, which suggests that although left sided extensions are common, right sided ablation suffices in many of these cases [23,24]. This in turn suggests some inter-connection between right and left sided atrial inputs. Indeed, prolongation of inter-atrial conduction time has been documented following conventional right sided slow pathway ablation denoting loss of this inter-connection [25]. Occasionally, the presence of left nodal extensions has been shown even in the lateral mitral annulus; masquerading as a left lateral accessory pathway which can be challenging to ablate [26]. The technique of using a late atrial extrastimulus from the inferolateral left atrium during AVNRT to advance the His and reset the tachycardia has been described to localize the ablation target [27]. Given the complexity and multiplicity of atrial extensions or breakthroughs from the AV node, it follows that the AVNRT circuit will need ablation from the left side in a few cases [28].

This is important to bear in mind as progressively higher levels of ablation on the right side due to lack of success will increase risk of AV block. Ablation confined to the inferior aspect of the triangle of Koch, with additional ablation within the coronary sinus or low left septum without moving to higher levels has been described as a safer approach to avoid AV block [29]. Taking this concept even further, Katritsis et al. have proposed only left sided ablation as an alternative approach to AVNRT ablation and demonstrated its feasibility in a small series of patients [30]. While such a strategy clearly needs further study, a systematic escalating approach for AVNRT ablation can be proposed, starting with the posteroseptal right atrium, moving little superiorly to the mid septum, followed by ablation inside the CS and finally the left posteroseptal and possibly even the lateral mitral annulus [31]. It is likely that ablation strategies will undergo further refinement in the near future as we achieve an even better understanding of the AVNRT circuit.

4.1. Limitations

Although we have described left sided ablation for AVNRT from a large series of patients, some limitations are acknowledged. This was a single centre study, and thus the results, including the proportion of AVNRT requiring left sided ablation, may not be generalizable across India or Asia. We mainly used an anatomical approach on both sides of the septum and did not systematically map slow pathway potentials. We also did not systematically use pacing or resetting manoeuvres from the mitral annulus which may have better delineated targets for ablation. Left sided ablation was confined to the posteroseptal mitral annulus and the lateral mitral annulus was not mapped; however grossly eccentric CS activation was not seen in any of our cases. Considering the small number of patients requiring left sided ablation, we could not identify any specific characteristics that would predict the need for left sided ablation. Further studies with larger numbers may be useful in this regard. Our understanding and approach towards difficult AVNRT cases continues to evolve and accumulating experience should lead to further refinement of strategies in the near future.

5. Conclusion

In this large series of consecutive AVNRT cases, left sided ablation helped eliminate arrhythmia in the small proportion of cases where extensive right sided ablation failed. A trans-septal

approach, anatomically targeting the posteroseptal mitral annulus yielded reasonable success, even in the absence of junctional ectopy during ablation. Left posterior extensions can be a key participant in the AVNRT circuit and left sided ablation is an important alternative strategy to bear in mind, both to maximize success and minimize potential risk in AVNRT ablation.

Disclosures

None.

CRediT authorship contribution statement

Kumar Narayanan: Conceptualization, Investigation, Methods, Formal Data analysis, Writing - original draft, Writing - review & editing. **Mohammed Omer:** Investigation, Data curation, Formal Data analysis. **Mohammed Arif:** Investigation, Data curation, Formal Data analysis. **Papani Sridhar:** Investigation, Resources, Writing - review & editing. **Nitin Annarapu:** Investigation, Resources, Writing - review & editing. **Shivaprasad Naidu:** Investigation, Resources, Writing - review & editing. **Pankaj Jariwala:** Investigation, Resources, Writing - review & editing. **Narasaraju Kavalipati:** Investigation, Resources, Writing - review & editing. **Mukharjee Madivada:** Investigation, Resources, Writing - review & editing. **Ramagiri Balaji:** Investigation, Resources, Writing - review & editing. **Premchand M:** Investigation, Resources, Writing - review & editing. **Sharath Reddy A:** Investigation, Resources, Writing - review & editing. **Anil Krishna G:** Investigation, Resources, Writing - review & editing. **Padmakumar EA:** Investigation, Resources, Writing - review & editing.

Declaration of competing interest

The authors hereby declare that they have no relevant conflict of interest to report with respect to this paper.

Appendix B. Supplementary data

Supplementary data related to this article can be found at <https://doi.org/10.1016/j.ipej.2020.10.004>.

References

- [1] Porter MJ, Morton JB, Denman R, Lin AC, Tierney S, Santucci PA, et al. Influence of age and gender on the mechanism of supraventricular tachycardia. *Heart Rhythm* 2004 Oct;1(4):393–6.
- [2] Page RL, Joglar JA, Caldwell MA, Calkins H, Conti JB, Deal BJ, et al. ACC/AHA/HRS guideline for the management of adult patients with supraventricular tachycardia: a report of the American college of cardiology/American heart association task force on clinical practice guidelines and the heart rhythm society. *Circulation* 2015;133(14):e506–74. 2016 Apr 5.
- [3] Billette J, Tadros R. An integrated overview of AV node physiology. *Pacing Clin Electrophysiol PACE* 2019;42(7):805–20.
- [4] Haissaguerre M, Gaita F, Fischer B, Commenges D, Montserrat P, d'Ivernois C, et al. Elimination of atrioventricular nodal reentrant tachycardia using discrete slow potentials to guide application of radiofrequency energy. *Circulation* 1992 Jun;85(6):2162–75.
- [5] Jackman WM, Beckman KJ, McClelland JH, Wang X, Friday KJ, Roman CA, et al. Treatment of supraventricular tachycardia due to atrioventricular nodal reentry by radiofrequency catheter ablation of slow-pathway conduction. *N Engl J Med* 1992 30;327(5):313–8.
- [6] Nakagawa H, Jackman WM. Catheter ablation of paroxysmal supraventricular tachycardia. *Circulation* 2007 Nov 20;116(21):2465–78.
- [7] Katritsis DG, Giazitzoglou E, Zografos T, Ellenbogen KA, Camm AJ. An approach to left septal slow pathway ablation. *J Interv Card Electrophysiol Int J Arrhythm Pacing* 2011 Jan;30(1):73–9.
- [8] Sorbera C, Cohen M, Woolf P, Kalapatapu SR. Atrioventricular nodal reentry tachycardia: slow pathway ablation using the transeptal approach. *Pacing Clin Electrophysiol PACE* 2000 Sep;23(9):1343–9.
- [9] Otomo K, Okamura H, Noda T, Satomi K, Shimizu W, Suyama K, et al. "Left-variant" atypical atrioventricular nodal reentrant tachycardia:

- electrophysiological characteristics and effect of slow pathway ablation within coronary sinus. *J Cardiovasc Electrophysiol* 2006 Nov;17(11):1177–83.
- [10] Heibüchel H, Jackman WM. Characterization of subforms of AV nodal reentrant tachycardia. *Eur Eur Pacing Arrhythm Card Electrophysiol J Work Groups Card Pacing Arrhythm Card Cell Electrophysiol Eur Soc Cardiol* 2004 Jul;6(4):316–29.
- [11] Nikoo MH, Attar A, Pourmontaseri M, Jorat MV, Kafi M. Atrioventricular nodal echoes over a wide echo window as a therapeutic end point for the catheter-guided radiofrequency ablation of atrioventricular nodal reentrant tachycardia: a prospective study. *Eur Eur Pacing Arrhythm Card Electrophysiol J Work Groups Card Pacing Arrhythm Card Cell Electrophysiol Eur Soc Cardiol* 2018 01;20(4):659–64.
- [12] Jais P, Haïssaguerre M, Shah DC, Coste P, Takahashi A, Barold SS, et al. Successful radiofrequency ablation of a slow atrioventricular nodal pathway on the left posterior atrial septum. *Pacing Clin Electrophysiol PACE* 1999 Mar;22(3):525–7.
- [13] Kilic A, Amasyali B, Kose S, Aytimir K, Celik T, Kursaklioglu H, et al. Atrioventricular nodal reentrant tachycardia ablated from left atrial septum: clinical and electrophysiological characteristics and long-term follow-up results as compared to conventional right-sided ablation. *Int Heart J* 2005 Nov;46(6):1023–31.
- [14] Katritsis DG, Marine JE, Contreras FM, Fujii A, Latchamsetty R, Siontis KC, et al. Catheter ablation of atypical atrioventricular nodal reentrant tachycardia. *Circulation* 2016 Nov 22;134(21):1655–63.
- [15] Katritsis DG, Zografos T, Siontis KC, Giannopoulos G, Muthalaly RG, Liu Q, et al. Endpoints for successful slow pathway catheter ablation in typical and atypical atrioventricular nodal re-entrant tachycardia: a contemporary, multicenter study. *JACC Clin Electrophysiol* 2019;5(1):113–9.
- [16] Ito K, Takemoto M, Mukai Y, Inoue S, Kaji Y, Chishaki A, et al. Radio-frequency catheter ablation of atypical atrioventricular nodal reentrant tachycardia from a trans-aortic approach. *Fukuoka Igaku Zasshi Hukuoka Acta Medica* 2009 Dec;100(12):360–5.
- [17] Nam G-B, Rhee K-S, Kim J, Choi K-J, Kim Y-H. Left atrionodal connections in typical and atypical atrioventricular nodal reentrant tachycardias: activation sequence in the coronary sinus and results of radiofrequency catheter ablation. *J Cardiovasc Electrophysiol* 2006 Feb;17(2):171–7.
- [18] Otomo K, Okamura H, Noda T, Satomi K, Shimizu W, Suyama K, et al. “Left-variant” atypical atrioventricular nodal reentrant tachycardia: electrophysiological characteristics and effect of slow pathway ablation within coronary sinus. *J Cardiovasc Electrophysiol* 2006 Nov;17(11):1177–83.
- [19] Ong MGY, Lee P-C, Tai C-T, Lin Y-J, Hsieh M-H, Chen Y-J, et al. The electrophysiologic characteristics of atrioventricular nodal reentry tachycardia with eccentric retrograde activation. *Int J Cardiol* 2007 Aug 9;120(1):115–22.
- [20] Randhawa A, Gupta T, Aggarwal A, Sahni D, Singh RS. Histological topography of the atrioventricular node and its extensions in relation to the cardiothoracic surgical landmarks in normal human hearts. *Cardiovasc Pathol Off J Soc Cardiovasc Pathol* 2017 Oct;30:38–44.
- [21] Inoue S, Becker AE. Posterior extensions of the human compact atrioventricular node: a neglected anatomic feature of potential clinical significance. *Circulation* 1998 Jan 20;97(2):188–93.
- [22] McGuire MA, de Bakker JM, Vermeulen JT, Moorman AF, Loh P, Thibault B, et al. Atrioventricular junctional tissue. Discrepancy between histological and electrophysiological characteristics. *Circulation* 1996 Aug 1;94(3):571–7.
- [23] Katritsis DG, Ellenbogen KA, Becker AE, Camm AJ. Retrograde slow pathway conduction in patients with atrioventricular nodal re-entrant tachycardia. *EPP Eur* 2007 Jul 1;9(7):458–65.
- [24] Katritsis DG, Becker AE, Ellenbogen KA, Giazitzoglou E, Korovesis S, Camm AJ. Effect of slow pathway ablation in atrioventricular nodal reentrant tachycardia on the electrophysiologic characteristics of the inferior atrial inputs to the human atrioventricular node. *Am J Cardiol* 2006 Mar 15;97(6):860–5.
- [25] Eksik A, Akyol A, Norgaz T, Erdinler I. Influence of atrioventricular nodal reentrant tachycardia ablation on right to left inter-atrial conduction. *Indian Pacing Electrophysiol J* 2005 Oct 1;5(4):279–88.
- [26] Hwang C, Martin DJ, Goodman JS, Gang ES, Mandel WJ, Swerdlow CD, et al. Atypical atrioventricular node reciprocating tachycardia masquerading as tachycardia using a left-sided accessory pathway. *J Am Coll Cardiol* 1997 Jul;30(1):218–25.
- [27] Stavrakis S, Jackman WM, Lockwood D, Nakagawa H, Beckman K, Elkholey K, et al. Slow/fast atrioventricular nodal reentrant tachycardia using the inferolateral left atrial slow pathway: role of the resetting response to select the ablation target. *Circ Arrhythm Electrophysiol* 2018;11(9):e006631.
- [28] Katritsis DG, Josephson ME. Classification, electrophysiological features and therapy of atrioventricular nodal reentrant tachycardia. *Arrhythmia Electrophysiol Rev* 2016 Aug;5(2):130–5.
- [29] Giazitzoglou E, Korovesis S, Kokladi M, Venetsanakos I, Paxinos G, Katritsis DG. Slow-pathway ablation for atrioventricular nodal re-entrant tachycardia with no risk of atrioventricular block. *Hell J Cardiol HJC Hell Kardiologike Epitheorese* 2010 Oct;51(5):407–12.
- [30] Katritsis DG, John RM, Latchamsetty R, Muthalaly RG, Zografos T, Katritsis GD, et al. Left septal slow pathway ablation for atrioventricular nodal reentrant tachycardia. *Circ Arrhythm Electrophysiol* 2018;11(3):e005907.
- [31] Kumar DS, Dewland TA, Balaji S, Henrikson CA. How to approach difficult cases of AVNRT. *Curr Treat Options Cardiovasc Med* 2017 May;19(5):34.