

Management Strategies of Cranial Encephaloceles: A Neurosurgical Challenge

Abstract

Background: Encephalocele is defined as herniation of cranial contents beyond the normal confines of the skull through a defect in the calvarium either along the midline or at the base of skull. These anomalies should be repaired in the first few months of life to prevent neurological deficits and facial disfigurement. The aim of the surgery is water tight dural closure at the level of internal defect, closure of skull defect, and reconstruction of external bony deformity. **Materials and Methods:** Fifty-four cases of encephaloceles were studied in our hospital over a 6-year period from 2010 to 2016. Computed tomography (CT) and magnetic resonance imaging (MRI) brain were performed to delineate the bony defect and associated anomalies. Reconstruction of the bony defect was done using autologous calvarial bone graft, Osteopore polycaprolactone (PCL) bone scaffold filler and titanium mesh. **Results:** In our study, 54 patients (34 boys and 20 girls) whose age varied between 2 months and 14 years were evaluated. Frontoethmoidal (44.5%) and occipital encephaloceles (25.9%) were the most frequently seen varieties. Repair of the dural defect either primarily or using pericranium was done in all cases. Closure of the bony defect was done using autologous calvarial bone graft in 12 (22.22%) patients. Titanium mesh was used in eight and Osteopore PCL bone scaffold filler in four children. Cranioplasty was not done in remaining thirty children because of the small bone defect. Overall, 80% had no postoperative problem and were discharged between 7 and 10 days of surgery. Cerebrospinal fluid leak was the most frequent postoperative complication, noted in five patients. Re-exploration with repair was done in one and remaining four were managed conservatively. Overall, cosmetic results were acceptably good, with parents judging the cosmetic outcome as good to excellent in 70%, satisfactory in 18%, and poor in 3% at the last follow-up. **Conclusion:** Our study demonstrated that encephaloceles are associated with complex deformities and pose a technical challenge to the neurosurgeon. A multidisciplinary approach is necessary to manage these cases. MRI brain and three dimensional CT aids in evaluating the deformity better and surgical correction should be performed as soon as possible to prevent a further neurological deficit. Repair of dural defect and reconstruction of the skull defect results in a good long-term outcome. We present our experience on 54 cases of cranial encephaloceles managed surgically over a period of only 6 years which is one of the largest series reported from Asia.

Keywords: Encephaloceles, multidisciplinary approach, reconstruction of bony deformity

Introduction

Encephalocele is defined as herniation of cranial contents beyond the normal confines of the skull through a defect in the calvarium either along the midline or at the base of skull.^[1] The contents may include the meninges (meningocele), meninges and brain (meningoencephalocele), or a part of ventricle (hydroencephalomeningocele). The type of encephalocele may be classified as occipital, parietal, basal, and sincipital or frontoethmoidal. Encephalocele is a common congenital problem faced in practice of neurosurgery worldwide. The overall incidence of encephaloceles is about 0.8–3.0/10,000 live births.^[2,3]

This is an open access journal, and articles are distributed under the terms of the Creative Commons Attribution-NonCommercial-ShareAlike 4.0 License, which allows others to remix, tweak, and build upon the work non-commercially, as long as appropriate credit is given and the new creations are licensed under the identical terms.

For reprints contact: reprints@medknow.com

Approximately, 75% of the encephaloceles are located in the occipital region^[4,5] followed by frontoethmoidal (13%–15%), parietal (10%–12%), or sphenoidal. Frontoethmoidal encephaloceles have a relatively high incidence (1:5000 live births) in Southeast Asia^[6] and are common in Malaysia, Thailand, and Burma. Basal meningoencephaloceles are rare, occurring in only 1 out of 35,000 live births.^[1] Treatment of frontoethmoidal encephaloceles should be recommended at an early age to avoid distortion of facial anatomy during growth. The absence of brain tissue within the sac is the single most favorable prognostic factor for survival.^[7] Computed tomography (CT) scan with three-dimensional reconstruction

How to cite this article: Velho V, Naik H, Survashe P, Guthe S, Bhide A, Bhople L, *et al.* Management strategies of cranial encephaloceles: A neurosurgical challenge. Asian J Neurosurg 2019;14:718-24.

Vernon Velho,
Harish Naik,
Pravin Survashe,
Sachin Guthe,
Anuj Bhide,
Laxmikant Bhople,
Amrita Guha¹

Departments of Neurosurgery and ¹Radiology, JJ Group of Hospitals and Grant Medical College, Mumbai, Maharashtra, India

Address for correspondence:

Dr. Harish Naik,
Department of Neurosurgery,
JJ Group of Hospitals and
Grant Medical College,
Mumbai - 400 008,
Maharashtra, India.
E-mail: haryadoc@gmail.com

Access this article online

Website: www.asianjns.org

DOI: 10.4103/ajns.AJNS_139_17

Quick Response Code:



is preferred for visualization of internal and external bony defects. Magnetic resonance imaging (MRI) can visualize the herniated contents within the sac and help in detecting other brain anomalies.^[8] Magnetic resonance angiography and venography have been shown to provide diagnostically useful information for evaluating normal and abnormal arterial and venous anatomy, dilated venous sinuses, and torcula in children and thus aid in proper surgical management.

Management of these anomalies requires a multidisciplinary team of neurosurgeon, neuroanesthetist, pediatric, maxillofacial, and plastic surgeon working in congruity. These anomalies should be repaired in the first few months of life because identification of intracranial connection is technically easier, and complete repair of dural defect is achieved. The aim of the surgery is water tight dural (intradural repair preferred over extradural repair) closure at the level of internal defect, closure of skull defect, resection of sac, and reconstruction of external bony deformity.^[9] Reconstruction of bony defect is achieved using either autologous calvarial bone graft or artificial mesh (titanium mesh or Osteopore bone scaffold filler).

The objectives of the present study were to present the long-term experience of the authors on the challenges in evaluation and integrated management of patients with encephaloceles. The results from analysis of these data can be used as current knowledge and applicable for recommendations for future clinical and surgical approaches to patients with encephaloceles. We report our experience in the management of these highly technically challenging cases.

Materials and Methods

This descriptive case series was conducted in our department during the period of 2010–2016. The case record of all the patients who were admitted with encephalocele was evaluated regarding age, sex, site and size of encephalocele, associated congenital cranial, and systemic abnormalities. Investigations such as skull radiographs, three-dimensional CT [Figure 1], and MRI brain [Figure 2a and b] were done. Additional procedures included lumbar drainage at the time of surgery or ventriculoperitoneal (VP) shunt (for hydrocephalus). All patients were considered for surgical correction. Children with occipital encephaloceles were operated in the lateral position [Figure 3a and b], and rest of the cases was operated in supine position [Figure 4]. In cases of large sac containing cerebrospinal fluid (CSF), head side of the operating table was kept down, and CSF was removed from the sac slowly as rapid drainage can lead to complications such as hypotension, subdural hematomas, or arrhythmias.

In frontonasal encephaloceles [Figure 5a and b], bicoronal incision was taken and frontal craniotomy done. Frontal lobe was retracted to define and repair the dural and bony

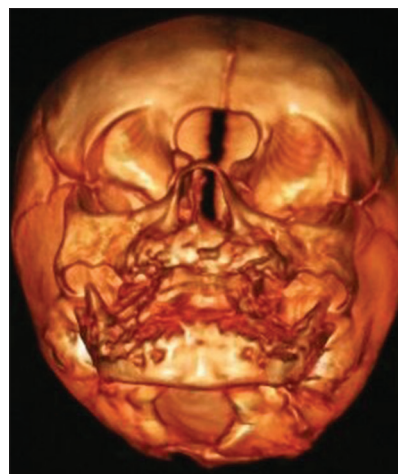

Figure 1: Computed tomography brain with three-dimensional reconstruction showing the skull defect in a case of frontonasal encephalocele

defect. Dysplastic brain tissue remaining in the sac was removed. Pericranium was applied to the floor of frontal lobes and reinforced with fibrin glue. Materials used in the reconstruction of the bony defect included autologous calvarial bone graft [Figure 6a and b] or artificial mesh-like titanium mesh or Osteopore bone scaffold filler.

Results

There were 54 admissions of patients with encephaloceles during the study period. Out of these, 34 (62.96%) were males, whereas 20 (37.03%) were females [Table 1]. Age range was 2 months to 14 years and 70% of the patients were infants [Table 2]. The most common type was frontoethmoidal seen in 44.5% children followed by occipital encephaloceles seen in 25.9% [Table 3]. All the patients of frontoethmoidal [Figure 7] subtype had a swelling either over bridge of the nose or at the root of the nose, with some degrees of hypertelorism. Most common content of the sac was meninges along with brain (meningoencephalocele) seen in 74.07% children [Table 4]. Repair of the dural defect either primarily or using pericranium was done in all cases. In our series, we have used fibrin glue to reinforce the duraplasty. Closure of the bony defect was done using autologous calvarial bone graft [Figure 8] in 22.22% patients [Table 5]. Titanium mesh [Figure 9] was used in eight children (14.65%) and Osteopore bone scaffold filler [Figure 10] in four children (7.40%). Six patients with hydrocephalus underwent VP shunt for CSF diversion before surgery. We used intraoperative lumbar drainage in 48 children (88.88%) [Table 6] which was continued in the postoperative period for 5–7 days.

Overall, 80% had no postoperative problem and were discharged between 7 and 10 days of surgery. CSF leak was the most frequent postoperative complication and recorded in five patients [Table 7]. However, by and large, CSF leak was transient and subsided with lumbar CSF drainage for

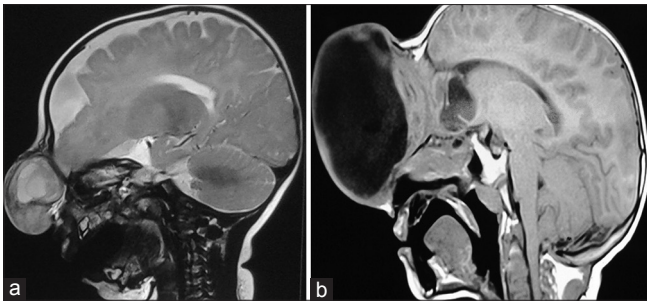


Figure 2: (a and b) Magnetic resonance imaging brain showing the herniated contents within the sac

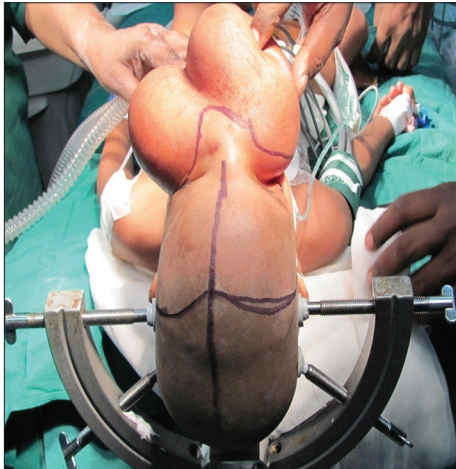

Figure 4: A case of bilobulated frontoethmoidal encephalocele who was placed in supine position on clamps during the surgery

Table 1: Sex distribution (n=54)

| Sex | Number of patients (%) |
|--------|------------------------|
| Male | 34 (62.96) |
| Female | 20 (37.03) |

Table 2: Age-wise distribution (n=54)

| Age | Number of patients (%) |
|-------------|------------------------|
| <6 months | 20 (37.03) |
| 7-12 months | 18 (33.33) |
| 1-3 years | 8 (14.81) |
| 3-12 years | 4 (7.40) |
| >12 years | 4 (7.40) |

Table 3: Type of encephaloceles (n=54)

| Type of encephalocele | Number of patients (%) |
|-----------------------|------------------------|
| Fronto ethmoidal | 24 (44.5) |
| Nasofrontal | 10 (18.5) |
| Nasoethmoidal | 6 (11.1) |
| Occipital | 14 (25.9) |

5–7 days. Only one patient required re-exploration, as CSF leak persisted beyond 7–10 days. One child developed postoperative meningitis, for which appropriate antibiotics were prescribed for a period of 2–3 weeks. The follow-up

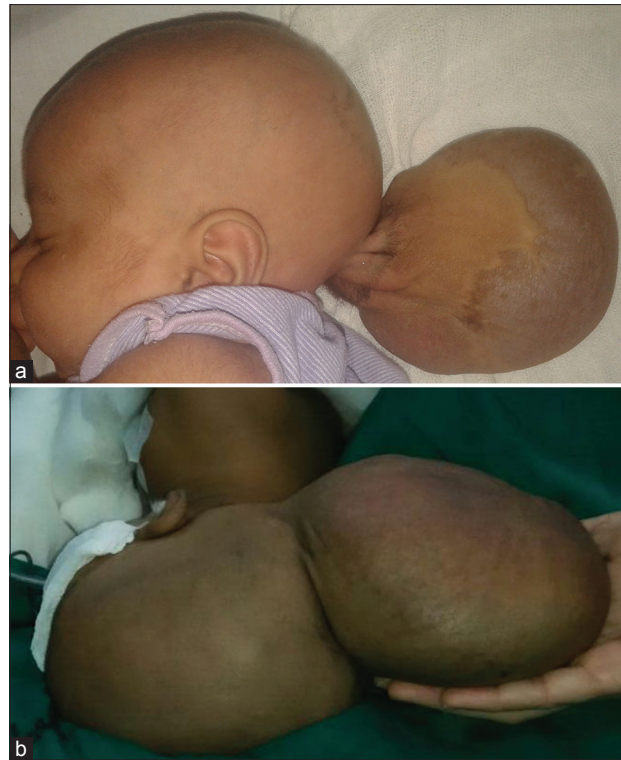

Figure 3: (a and b) Two cases of occipital encephalocele who were placed in lateral position and operated

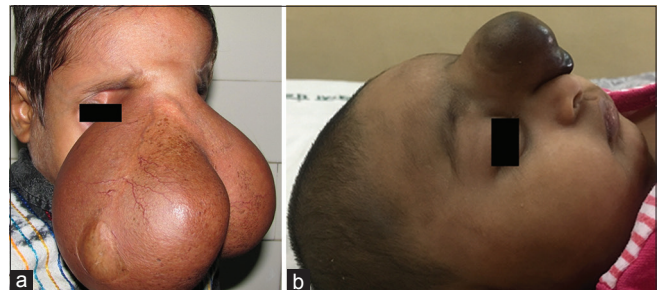


Figure 5: (a) A case of one of the largest frontonasal encephalocele encountered in our series and (b) another case of frontonasal encephalocele

period ranged from 3 months to 5 years, with a mean of 3 years. Overall, cosmetic results were acceptably good, with parents judging the cosmetic outcome [Table 8] as good to excellent in 70% [Figure 11a, b, and c], satisfactory in 18%, and poor in 3% at last follow-up. However, some patients may need cosmetic surgery, including rhinoplasty or eyelid repair at a later stage, depending on soft tissue abnormalities, for which they were referred to cosmetic surgeons of our hospital. We do not routinely perform neuropsychological assessment in these patients because in the absence of gross brain herniation or damage, encephaloceles are usually associated with normal intelligence and motor development.

Discussion

This study was carried out in our neurosurgery department attached to a large tertiary care referral hospital and

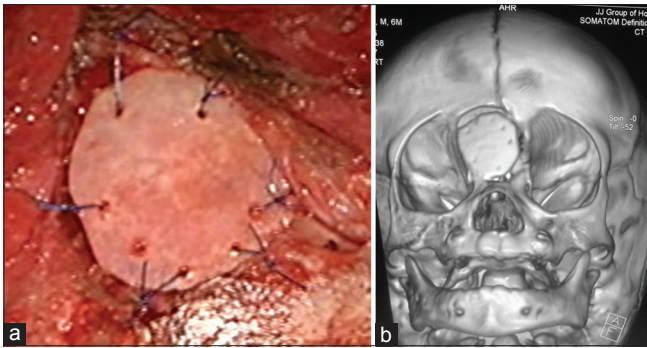


Figure 6: (a) Reconstruction of the bony defect done by autologous bone graft and (b) Three dimensional computed tomography showing the bony defect covered by autologous bone graft

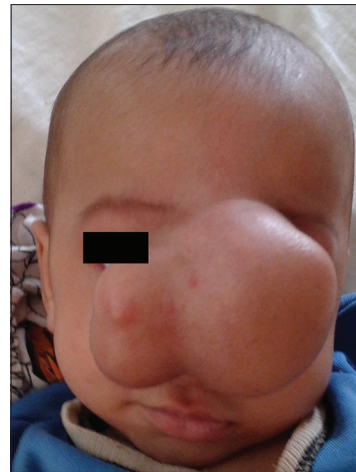

Figure 7: A case of frontoethmoidal encephalocele with a swelling at the root of the nose

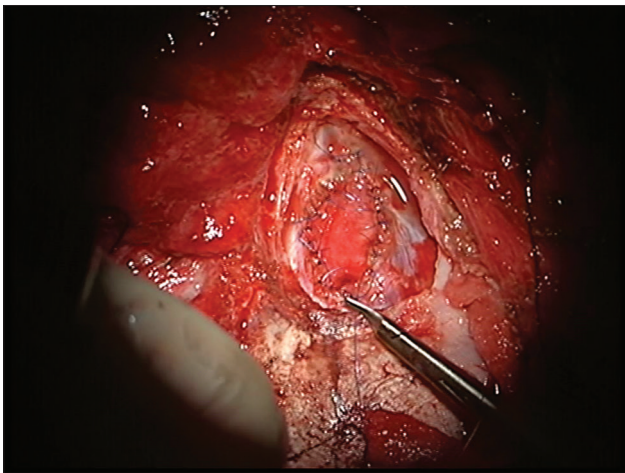


Figure 8: Operative photograph showing watertight closure of the dural defect by pericranium

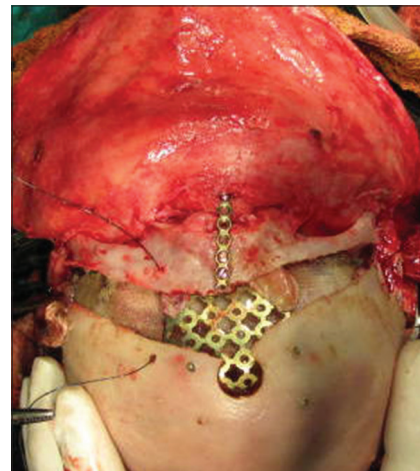


Figure 9: Intraoperative photograph showing reconstruction of the skull defect by titanium mesh

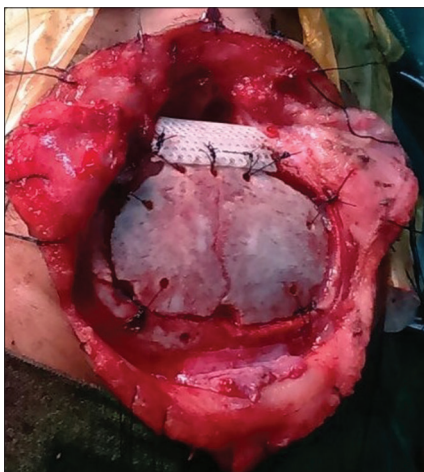

Figure 10: Intraoperative photograph showing reconstruction of the skull defect by Osteopore bone scaffold filler

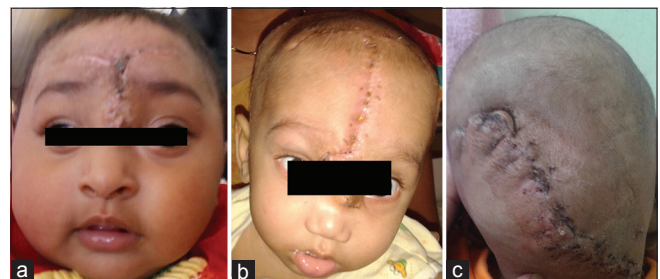

Figure 11: (a) Follow-up photograph of a child with frontonasal encephalocele who is shown in Figure 5b (taken after 3 months of surgery), (b) follow-up photograph of a child with frontoethmoidal encephalocele who is shown in Figure 7 (taken after 3 months of surgery), (c) follow-up photograph of a child with occipital encephalocele who is shown in Figure 3b (taken after 3 months of surgery)

consequently is subject to all the biases inherent in a hospital study. Various theories have been put forth regarding the etiopathogenesis of this disorder with one of the popular ones by De Klerk and De Villiers, who suggested that adhesions between the neuroectoderm and the surface ectoderm may prevent the normal ingrowth of mesoderm to

form a normal skull.^[10] Despite the reduction of incidence of neural tube defects (NTDs) in the West, in countries like India, NTD is a major problem for the neurosurgeons in view of the technical challenges in managing these cases. Ours being a tertiary referral center, we get a large number of patients with NTD including encephaloceles.

Overall, encephaloceles are rare, and we have managed 54 cases over a period of 6 years. Seventy percent patients were <1 year of age and 10% were older than 5 years. The authors recommend delaying surgical treatment to the age of 5–10 months to minimize complications from anesthesia (i.e., blood loss and hypothermia) as most of the operations are prolonged. Surprisingly, more than 30% patients reported to us after 1 year. Lack of awareness on the part of general practitioners and pediatricians delayed the referral to a tertiary center. Table 9 summarizes the classification system for cranial encephaloceles based on the location of the skull defect.^[11]

Frontal encephaloceles are further divided into sincipital or frontoethmoidal (60%) and basal (40%). The site of the sincipital encephalocele is at the cranial end of the defect through an internal skull defect at the area of the foramen cecum at the junction of the frontal and ethmoidal bones. These swellings are either sessile or pedunculated and on palpation may vary from being solid and firm to soft and cystic type. The skin over the mass may be normal in appearance, thin and shiny, or thick and wrinkled.

Sincipital encephaloceles are classified according to the location of the external skull defect as nasofrontal, naso-ethmoidal, or naso-orbital, with some overlap or multiplicity.^[11] An extensive evaluation is mandatory in every patient with encephalocele to arrive at an accurate diagnosis, thoroughly delineate the malformed anatomy, classify the deformities, evaluate the associated anomalies, make a prognosis, conduct surgical planning, and determine the outcomes to measure throughout the treatment trajectory.

The objectives of the reconstruction are (a) closure of open skin defects to prevent infection and desiccation of viable brain tissue, (b) removal or invagination of nonfunctional extracranial cerebral tissue, and (c) water-tight closure of the dura and craniofacial reconstruction with particular emphasis on exact skeletal reconstruction.

Children with frontoethmoidal encephalocele should have early surgical correction to treat and prevent facial deformities, impairment of binocular vision, increasing size of the swelling by secondary herniation of intracranial contents, and risk of infection of the central nervous system. The treatment of associated brain anomalies (such as hydrocephalus) should be the first priority, and subsequently, a one-stage reconstructive procedure can be performed.^[9,12-14]

The surgical techniques to reconstruct the deformities caused by frontoethmoidal encephalocele include (a) combined intra- and extra-cranial procedures (bicoronal incision, nasofrontal bone flap, and facial reconstruction)^[15,16] or (b) an extracranial procedure only^[17,18] according to the pattern of the patient’s malformation and the availability of neurosurgical expertise.

Frontoethmoidal encephaloceles appear to have a more favorable outcome than occipital or parietal

Table 4: Contents of sac (n=54)

| Finding | Number of patients (%) |
|---------------------------|------------------------|
| Meningocele | 10 (18.5) |
| Meningoencephalocele | 40 (74.07) |
| Hydromeningoencephalocele | 4 (07.40) |

Table 5: Type of cranioplasty (n=24)

| Type of closure | Number of patients (%) |
|---------------------------------|------------------------|
| Autologous calvarial bone graft | 12 (22.22) |
| Titanium mesh | 8 (14.81) |
| Osteopore bone scaffold filler | 4 (07.40) |

Table 6: Type of cerebrospinal fluid diversion (n=54)

| CSF diversion | Number of patients (%) |
|---------------|------------------------|
| Lumbar drain | 48 (88.88) |
| VP shunt | 6 (11.12) |

CSF – Cerebrospinal fluid; VP – Ventriculoperitoneal

Table 7: Complications (n=54)

| Complication | Number of patients (%) |
|-----------------|------------------------|
| CSF leak | 5 (9.25) |
| Meningitis | 1 |
| Wound infection | 1 |

CSF – Cerebrospinal fluid

Table 8: Surgical outcome (n=54)

| Outcome | Number of patients (%) |
|--------------|------------------------|
| Excellent | 10 (18.65) |
| Good | 26 (48.06) |
| Satisfactory | 10 (18.65) |
| Unchanged | 6 (11.16) |
| Poor | 2 (03.78) |

Table 9: Classification of encephaloceles

| Type | Site of herniation | Location of mass |
|------------------|---------------------------------------|---------------------------|
| I. Occipital | | |
| II. Frontal | | |
| Sincipital | | |
| Nasofrontal | Fonticulus nasofrontalis | Forehead: Nasal bridge |
| Nasoethmoidal | Foramen cecum | Nasal bridge |
| Naso-orbital | Medial orbital wall | Orbit |
| Basal | | |
| Transethmoidal | Cribriform plate | Intranasal |
| Sphenoethmoidal | Between ethmoid and sphenoid | Nasopharynx |
| Trans sphenoidal | Craniopharyngeal canal | Nasopharynx |
| Sphenomaxillary | Superior and inferior orbital fissure | Pterygopalatine fossa |

meningoencephaloceles: an overall mortality of 7%–20% with a favorable developmental outcome has been

reported.^[12,16] The prognosis is mainly determined by the presence of associated hydrocephalus or additional congenital anomalies of brain.^[19]

Basal meningoencephaloceles are the rarest type. As a result, it is virtually impossible to obtain sufficient experience to form scientific guidelines for the management of these difficult congenital abnormalities. Basal encephaloceles are also divided into transthemoidal, sphenoethmoidal, transsphenoidal, and sphenomaxillary and manifest as smooth masses intranasally or in the areas of nasopharynx and pterygopalatine fossa, depending on the site of herniation at the skull base [Table 9]. Basal encephaloceles may present with nasal obstruction or symptoms related to herniation of basal structures. Strabismus and lacrimal obstructions, resulting in epiphora and/or dacryocystitis, can be observed. The indications for surgery in basal encephaloceles are nasopharyngeal obstruction, recurrent meningitis, visual disturbances, and endocrine disturbances.

Complete removal of the dysplastic tissue will allow the developing brain and eyes to mold the orbital skeleton and allow development of a proper nasal airway, speech, and mastication.

Occipital encephaloceles can vary from a small swelling to an extremely large one. Occipital encephalocele is described as giant when they are larger than the head from which they arise.^[20,21]

Giant occipital encephalocele is a rare and this clinical condition is anxious to neurosurgeon, pediatrician, and anesthesiologist. There are numerous challenges (preoperative, surgical, and postoperative) because of their enormous size these poses. In the preoperative period, operating room, and postoperative period, we could not place the babies supine. Presence of giant occipital encephalocele poses difficulties in positioning for intubation. All neonates were positioned in the lateral position and induced anesthesia. In all cases, endotracheal intubation was achieved through the lateral position. There were no ventilation problems in any of the neonates during intraoperative period. Lateral position is considered to be safer than the supine position because the weight of the head is not transmitted to the sac; this eliminates the risk of compression-related preoperative rupture of the sac or an inadvertent increase in the intracranial pressure. The surgery of neonate with giant occipital encephalocele with herniation of considerable amount of brain tissue into the sac can be extremely difficult. Usually, giant encephaloceles contain degenerative cerebral cortex presuming its noneloquent function. Timing of the surgery is recommended to be done as soon as possible to save the child's life-threatening conditions such as respiratory distress, improve child's development, and decrease the incidence of infection such as CNS infections, aspirated pneumonias, and irreversible damage of nucleus ambiguus for vagus nerve.

If the calvarial defect is small, no cranioplasty of the bone defect is necessary. A cranioplasty to cover the larger defects can be performed for cosmetic state. The cranioplasty can be performed after excision of the sac during surgery or at a later date. Methyl methacrylate, hydroxapatite bone cement, demineralized bone matrix, titanium meshes, autologous graft-like the rib, or autologous calvarial bone graft have been used in the literature.^[22]

In our series, the dysplastic brain tissue which was coming out of skull was removed. In all the occipital, parietal, and nasal encephaloceles, dysplastic brain tissue was removed safely. The presence of gross brain tissue in a sac of occipital encephaloceles, associated hydrocephalus, and other congenital anomalies are unfavorable factors for prognosis compared to the parietal and sincipital encephaloceles.

Conclusion

Our study demonstrated that encephaloceles are associated with complex deformities and pose a technical challenge to the neurosurgeon. Experience demonstrated that a craniofacial center with interdisciplinary management was necessary to provide proper, early, and longitudinal care and to achieve optimum outcomes for the patients with encephaloceles. The collaboration between neurosurgeon and maxillofacial surgeon and neuro-pediatric anesthesiologist is fundamental in this disease.

In each case, the surgical outcome depends on the severity and classification of the deformities and the extent of associated brain anomalies. The role of imaging, particularly MRI brain and three-dimensional CT aids in evaluating the deformity better. Surgical correction should be performed as soon as possible to prevent further neurological deficit. Repair of dural defect and reconstruction of the skull defect results in good to excellent cosmetic outcome and may be achieved in the majority of the patients, with minimal morbidity and mortality.

Declaration of patient consent

The authors certify that they have obtained all appropriate patient consent forms. In the form the patient(s) has/have given his/her/their consent for his/her/their images and other clinical information to be reported in the journal. The patients understand that their names and initials will not be published and due efforts will be made to conceal their identity, but anonymity cannot be guaranteed.

Financial support and sponsorship

Nil.

Conflicts of interest

There are no conflicts of interest.

References

1. French BN. Midline fusion defects and defects of formation. In: Youmans JR, editor. *Neurological Surgery*. 6th ed. Philadelphia:

- Saunders; 1990. p. 1081-85.
2. McLone DG. Congenital malformations of the central nervous system. *Clin Neurosurg* 2000;47:346-77.
 3. Lo BW, Kulkarni AV, Rutka JT, Jea A, Drake JM, Lamberti-Pasculli M, *et al.* Clinical predictors of developmental outcome in patients with cephalocele. *J Neurosurg Pediatr* 2008;2:254-7.
 4. Arora P, Mody S, Kalra VK, Altaany D, Bajaj M. Occipital meningoencephalocele in a preterm neonate. *BMJ Case Rep* 2012;2012. pii: bcr2012006293.
 5. Bozinov O, Tirakotai W, Sure U, Bertalanffy H. Surgical closure and reconstruction of a large occipital encephalocele without parenchymal excision. *Childs Nerv Syst* 2005;21:144-7.
 6. Suwanwela C. Geographical distribution of fronto-ethmoidal encephalomeningocele. *Br J Prev Soc Med* 1972;26:193-8.
 7. Brown MS, Sheridan-Pereira M. Outlook for the child with a cephalocele. *Pediatrics* 1992;90:914-9.
 8. Naidich TP, Altman NR, Braffman BH, McLone DG, Zimmerman RA. Cephalocele and related malformations. *AJNR Am J Neuroradiol* 1992;13:655-90.
 9. Smit CS, Zeeman BJ, Smith RM, de V Cluver PF. Frontoethmoidal meningoencephalocele: A review of 14 consecutive patients. *J Craniofac Surg* 1993;4:210-4.
 10. De Klerk DJ, De Villiers JC. Frontal encephalocele. *S Afr Med J* 1973;47:1350-5.
 11. Suwanwela C, Suwanwela N. A morphological classification of sincipital encephalomeningocele. *J Neurosurg* 1972;36:201-11.
 12. Macfarlane R, Rutka JT, Armstrong D, Phillips J, Posnick J, Forte V, *et al.* Encephalocele of the anterior cranial fossa. *Pediatr Neurosurg* 1995;23:148-58.
 13. David DJ. Cephalocele: Classification, pathology, and management – A review. *J Craniofac Surg* 1993;4:192-202.
 14. Forcada M, Montandon D, Rilliet B. Frontoethmoidal cephalocele: Transcranial and transfacial surgical treatment. *J Craniofac Surg* 1993;4:203-9.
 15. Boonvisut S, Ladpli S, Sujatanond M, Tandhavadhana C, Tisavipat N, Luxsuwong M, *et al.* Morphologic study of 120 skull base defects in frontoethmoidal encephalomeningocele. *Plast Reconstr Surg* 1998;101:1784-95.
 16. Holmes AD, Meara JG, Kolker AR, Rosenfeld JV, Klug GL. Frontoethmoidal encephalocele: Reconstruction and refinements. *J Craniofac Surg* 2001;12:6-18.
 17. Holm C, Thu M, Hans A, Martina M, Silvia GS, Moritz S, *et al.* Extracranial correction of frontoethmoidal meningoencephalocele: Feasibility and outcome in 52 consecutive cases. *Plast Reconstr Surg* 2008;121:386e-395e.
 18. Rosenfeld JV, Watters DA. Surgery in developing countries. *J Neurosurg Pediatr* 2008;1:108.
 19. Hoving EW, Vermeij-Keers C. Frontoethmoidal encephalocele, a study of their pathogenesis. *Pediatr Neurosurg* 1997;27:246-56.
 20. Singh H, Singh D, Sharma D, Tandon MS, Ganjoo P. Perioperative challenges in patients with giant occipital encephalocele with microcephaly and micrognathia. *J Neurosci Rural Pract* 2012;3:68-70.
 21. Agarwal A, Chandak AV, Kakani A, Reddy S. A giant occipital encephalocele. *APSP J Case Rep* 2010;1:16.
 22. Mohanty A, Biswas A, Reddy M, Kolluri S. Expansile cranioplasty for massive occipital encephalocele. *Childs Nerv Syst* 2006;22:1170-6.