



## A RARE CASE SCENARIO OF MULTIPLE MYELOMA

Dr. Arpita Mishra Department of Biochemistry, SRL Diagnostic Pvt Ltd, Mumbai, Maharashtra, India

**ABSTRACT** **Introduction:** Multiple Myeloma (MM) constitutes for 10% of all haematological malignancies and 1% of all malignancies. They cover a wide spectrum of diseases from the premalignant condition Monoclonal Gammopathy of Undetermined Significance(MGUS) to symptomatic Multiple Myeloma, Malignant Lymphomas, and Chronic Lymphocytic Leukaemia (CLL). **Objective:** Presenting a case report of a rare case of Multiple Myeloma which does not quite well fit into the said subclassifications. **Result:** Serum free light chain ratio is normal with M spike. **Conclusion:** A patient presenting with clinical features of multiple myeloma should undergo extensive work up for not only correct diagnosis but also for follow up.

**KEYWORDS :** Multiple Myeloma, Serum Free Light Chains, Immunofixation, IFE, SPEP, Serum Protein Electrophoresis

## INTRODUCTION AND BACKGROUND

Multiple Myeloma(MM) constitutes for 10% of all haematological malignancies and 1% of all malignancies [1]. It is a malignant disease characterized by abnormal proliferation of plasma cells and monoclonal immunoglobins or free light chains(FLC).The annual incidence of MM is 7.74 per 100,000 population while the annual number of deaths due to MM is 3.52 per 100,000 population.[2,3] The median age in patients with MM at the time of diagnosis is 65 years.[4] . Monoclonal gammopathy is a hallmark of plasma cell dyscrasias and some B-cell lymphoproliferative disorders. They cover a wide spectrum of diseases from the premalignant condition Monoclonal Gammopathy of Undetermined Significance (MGUS) to symptomatic Multiple Myeloma, Malignant Lymphomas, and Chronic Lymphocytic Leukaemia (CLL). Their ability to cause kidney disease is another important characteristic.[5] Clinical manifestations include osteolytic bone lesions, anaemia, hypercalcemia, renal insufficiency, and an increased risk of infections. Bone disease is the major cause of morbidity in patients with MM and can be detected on skeletal radiographs.[6] Smoldering Multiple Myeloma (SMM) is an intermediate stage between MGUS and MM.The M protein type is IgG in approximately 50%, IgA in 20%, immunoglobulin light chain only in 20%, IgD in 2%, and IgM in 0.5%. About 2–3% of MM has no detectable M protein, and is referred to as non-secretory MM.[7]

## CASE REPORT

Sample received for Complete Myeloma Profile for 62-year-old male in our laboratory. After processing the sample we found out that in Serum Protein Electrophoresis(SPEP) there is a M band with a clonality of IgGKappa.(As reported in Immunofixation electrophoresis). Furthermore, into investigation, we found out that his serum free light chains are completely normal which is a very rare case scenario. After discussion with the Referring Clinician we found out that, this 62 year male presented with a 6-month history of progressive polyarthralgia, joint swelling with anaemia and fatigue. On MRI Spine, he has multiple lytic lesions.

Fresh sample for this patient was requested and re analysis was done with the fresh sample. Unexpectedly we got the same result with Myeloma peak with clonality of IgGKappa and serum free light chains normal. Then we performed serum total light chain assay and found out that serum total kappa was raised.

## RESULT

The results are summarized in the figures and tables below:




Fig 1: SERUM PROTEIN ELECTROPHORESIS GRAPH (Showing Mspike of IgM/dl)

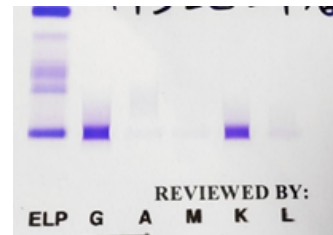


Fig 2: SERUM IMMUNOFIXATION (Showing M Band of Clonality IgGKappa)

Table No.1: Specific Laboratory Investigations

Test Description	Observed Value	Reference Range
Serum Beta-2-microglobulin	2837	609-2366 ng/ml
Serum Free Kappa(light chain)	18	3.30-19.40 mg/L
Serum Free Lambda (light chain)	16.9	5.71-26.30 mg/L
Serum Free Kappa/Lambda(light chain)	1.065	0.26-1.65
Serum Total Kappa	7880	1700-3700 mg/L
Serum Total Lambda	777	900-2100 mg/L
Serum Total Kappa/Lambda	10.14	1.35-2.65
Ig A level, serum by nephelometry	0.89	1.03-5.91 g/L
Ig G level, serum by nephelometry	22.3	6.6-16.9 g/L
Ig M level, serum by nephelometry	0.19	0.37-2.58 g/L
<b>Serum Electrophoresis:</b>		
Serum Total proteins	8.3	6-8 g/dl
Serum Albumin	3.97	3.30-5.70 g/dl
Alpha 1 globulin	0.6	0.10-0.40 g/dl
Alpha 2 globulin	1.14	0.30-0.90 g/dl
Beta 1 globulin	0.43	0.30-0.70 g/dl
Beta 2 globulin	0.27	0.10-0.50 g/dl
Gamma globulin	1.89	0.50-1.60 g/dl
Albumin:Globulin ratio	0.92	1.1-2.2g/dl
M Band	Detected	
M spike	1	g/dl
<b>Serum Immunofixation:</b>		
Myeloma Band	Detected	
IgG Band	Detected	
IgM Band	Not Detected	
IgA Band	Not Detected	
Kappa Band	Detected	
Lambda Band	Not Detected	

## DISCUSSION

Multiple Myeloma is a consequence of abnormal plasma cell proliferation in the bone marrow and accounts for 10% of the haematological malignancies. SPEP remains a gold standard test and is mostly used to detect the M protein spike in myeloma patient. The confirmation of the diagnosis is aided by biochemical, radiological, and histological findings.[8] All the subtypes of Multiple Myeloma need to be comprehensively studied to aid in reaching an accurate diagnosis.

## CONCLUSION

In conclusion, a patient presenting with clinical features of multiple myeloma should undergo extensive work up involving CBC, serum chemistry, protein electrophoresis, immunofixation, free light chain studies, radiologic imaging, and bone marrow biopsy to conclude diagnosis of multiple myeloma with respect to their subtypes. The serum free light chains cannot only be used for follow-up patients since sometimes they can be normal with M spike present. For follow-up as well, complete work up is essential.

## REFERENCES

1. Multiple myeloma:2014 Update on diagnosis, risk stratification, and management. Rajkumar SV. *Am J Hematol.* 2014;89:998-1009. [PubMed][Google Scholar]
2. Serum N-glycans: a new diagnostic biomarker for light chain multiple myeloma. Chen J, Fang M, Zhao YP, et al. *PLoS One.* 2015;10:127022. [PMC free article] [PubMed] [Google Scholar]
3. Cancer statistics, 2014. Siegel R, Ma J, Zou Z, et al. *CA Cancer J Clin.* 2014;64:9-29. [PubMed] [Google Scholar]
4. Multiple myeloma: 2016 update on diagnosis, risk-stratification, and management. Rajkumar SV. *Am J Hematol.* 2016;91:719-734. [PMC free article] [PubMed] [Google Scholar]
5. Clinical Tests for Monoclonal Proteins-Nelson Leung, MD (Division of Nephrology and Hypertension, Hematology, Mayo Clinic, Rochester, Minnesota)
6. Comparison of modern and conventional imaging techniques in establishing multiple myeloma-related bone disease: a systematic review. Regelink JC, Minnema MC, Terpos E, et al. *Br J Haematol.* 2013;162:50-61. [PubMed] [Google Scholar]
7. Multiple Myeloma: Diagnosis and Treatment-S. Vincent Rajkumar, M.D. and Shaji Kumar, M.D. (*Mayo Clin Proc.* 2016 Jan;91(1): 101-119.)
8. Dash NR, Mohanty B: Multiple myeloma: a case of atypical presentation on protein electrophoresis. *Indian J Clin Bioche.* 2012;27:100-102.