


Original Research Article

A study of bleeding per rectum in cirrhosis patients: Role of portal hypertensive colopathy – A tertiary care center experience

M. Umadevi^{1*}, NSVM Krishna², P Abhinay Rajarao², Anirudh², Sriram², Samad², Swapnika², Sai Krishna³, Issac Abhilash³, P. Shrvan Kumar⁴

¹Associate Professor, ²Post Graduate, ³Assistant Professor, ⁴Professor
Dept. of Gastroenterology, Gandhi Medical College, Secunderabad, India

*Corresponding author email: umadevimalladi_66@yahoo.co.in

	International Archives of Integrated Medicine, Vol. 7, Issue 10, October, 2020. Available online at http://iaimjournal.com/ ISSN: 2394-0026 (P) ISSN: 2394-0034 (O)
	Received on: 18-09-2020 Accepted on: 04-10-2020 Source of support: Nil Conflict of interest: None declared.
How to cite this article: M. Umadevi, NSVM Krishna, P Abhinay Rajarao, Anirudh, Sriram, Samad, Swapnika, Sai Krishna, Issac Abhilash, P. Shrvan Kumar. A study of bleeding per rectum in cirrhosis patients: Role of portal hypertensive colopathy – A tertiary care center experience. IAIM, 2020; 7(10): 42-50.	

Abstract

Background: In patients with cirrhosis of liver, exact cause of lower gastrointestinal (GI) bleeding is important for evaluation, management and prognosis. Lesions like portal hypertensive colopathy (PHC) and anorectal varices (ARVs) are thought to cause. In the present work, we studied the diagnostic yield of colonoscopy in cirrhotic patients and hematochezia.

Materials and methods: The current study was conducted on 77 consecutive cirrhotic patients who underwent colonoscopy at Gandhi Hospital Secunderabad, between October 2012 and December 2019. Following rapid evaluation and adequate resuscitation in emergency ward, a thorough history was obtained with complete physical examination including digital rectal examination and routine laboratory investigations. Colonoscopic evaluation was performed for the included patients by recording endoscopic abnormalities and obtaining biopsies from lesions.

Results: There was no significant difference between the PHC-positive group when compared with the PHC-negative group regarding patients' age, sex, and severity of hematochezia, positive family history and the history of intake of non-steroidal anti-inflammatory drugs (NSAIDs). Significant difference was noted regarding the Child–Pugh class, prior history of endoscopic sclerotherapy (EST)

or endoscopic variceal ligation (EVL) ($p <$ prior history of upper gut bleeding, the presence of gastric varices (GVs), presence of portal hypertensive gastropathy (PHG), presence of hemorrhoids and rectal varices. Regarding the laboratory parameters, the platelet count only was markedly reduced in the PHC-positive group. All the PHC-related sources of bleeding (7/32 cases (21.87%)) were successfully managed with argon plasma coagulation. Regarding the laboratory parameters, the platelet count only was markedly reduced in the PHC-positive group. All the PHC-related sources of bleeding (7/32 cases (21.87%)) were successfully managed with argon plasma coagulation.

Conclusion: Our study showed early colonoscopy in cirrhosis patients reveal exact cause of bleeding to take appropriate intervention and correction of coagulation abnormalities helps in prompt early recovery and it is not only PHC which is involved in hematochezia in cirrhotic patients despite the significant association.

Key words

Bleeding per rectum, Cirrhosis, Portal hypertension, Colopathy.

Introduction

Hematochezia is the passage of bright red or maroon blood from the rectum. Its prevalence in the apparently healthy general population ranges between 9% and 19% [1, 2]. Rectal bleeding is approximately one-fifth as common as upper GI bleeding and accounts for 20–30 hospitalizations per 100000 per year [3, 4].

Bright red blood is usually from the colon or rectum; however, in the presence of severe blood loss, it may be due to an upper gastrointestinal (GI) source with rapid GI transit [5]. Generally, acute bleeding from the colon is self-limited and less dramatic than upper GI bleeding. Advanced age, recurrent bleeding and co-morbidities are the most common factors incriminated for substantial patients' morbidity and mortality [6]. However, still little is known about the role of colonoscopy in the evaluation of rectal bleeding in cirrhotic patients. The investigation aims to study the diagnostic yield of colonoscopy in patients with liver cirrhosis presented with rectal bleeding.

Colonoscopy is the diagnostic and therapeutic procedure of choice for evaluation of acute lower GI bleeding with a high diagnostic yield and very low incidence of serious complications [7, 8].

In patients with liver cirrhosis and portal hypertension, varices of the esophagus, stomach and portal hypertensive gastropathy (PHG) are well described [9]. Most patients bleed from benign sources such as hemorrhoids and diverticulae, but others have serious colorectal diseases including colorectal cancer (CRC), adenomatous polyps and inflammatory of interest is that 7–10% of patients with overt rectal bleeding did in fact have CRC [10]. These complications are most common causes of upper GI hemorrhage. On the other hand, PHC [11] and Anorectal varices (ARV) that have been identified in 40% of patients with liver cirrhosis are thought to be important causes of lower GI hemorrhage [12] while colonic varices are rare causes of such a gut bleeds.

The mucosal abnormalities described well as Portal hypertensive colopathy (PHC) and constitutes the following [11] was considered as

A.Mild: if documented mucosal edema, diffuse hyperemia, granularity and/or friability were present.

B.Severe grade: with evident vascular ectasias, angiodysplasia, arterial spiders and diffuse cherry red spots.

Arterial spider-like lesion: An arterial spider-like lesion was defined as the presence of a central arteriole from which numerous small

vessels radiate, which blanch with pressure with a biopsy forceps.

Angiodysplasia-like lesion: The angiodysplasia-like lesion has a fern-like vascular pattern with an irregular margin.

Diffuse red spots: Diffuse red spots are defined by the presence of red spots in the colonic mucosa similar to that seen in the gastric mucosa in PHG.

Vascular irregularity: Vascular irregularity was defined as the presence of a submucosal coil-like appearance with an arc-shaped tip of blood vessels vascular dilatation.

Vascular dilatation: Vascular dilatation was made when numerous prominent veins of more than 3-6 mm were observed in a colonic segment.

The pathogenesis of PHC-related abnormal vascular lesions is unclear. Ischemia and/or hypoxia of the intestinal mucosa caused by the changes in the splanchnic hemodynamics may produce capillary proliferation, vascular dilatation and arteriovenous malformations, and consequently capillary fragility [12, 13].

Materials and methods

All patients with hematochezia and PHC were Child–Pugh class B and had low platelet count. The majority of the patients included in our study were due to cirrhosis of alcoholic etiology that is well known to cause thrombocytopenia which is a significant causal factor for hematochezia.

For all enrolled patients, data were collected including: patient demographics, indications for colonoscopy, endoscopic (upper and lower) findings and histopathology results for those in whom biopsies were taken. Ethical approval was granted by the Gandhi Medical college ethics Committee.

Patients and methods

The studied patients, after giving written well-informed consent, were immediately managed by rapid initial evaluation for hemodynamic instability as a result of blood loss, then, rapid

and adequate resuscitative measures for those with poor hemodynamic status. After stabilization thorough history taking and complete physical examination including general, local abdominal and digital rectal examination; laboratory evaluation of the included patients by complete blood count (CBC), hematocrit value, erythrocyte sedimentation time (ESR), prothrombin time, partial thromboplastin time, serum creatinine, blood glucose, electrolytes, serum bilirubin, alanine aminotransferase (ALT) and aspartate aminotransferase (AST).

All patients were admitted either to the intensive care unit or to general wards for proper management. A decrease in the hematocrit value of at least 6%, a transfusion requirement of more than two units of packed red blood cells or continuous active bleeding necessitate admission to an intensive care unit. The presence of coagulopathy or thrombocytopenia was promptly corrected with transfusion of fresh-frozen plasma or platelets, respectively.

Patients with ongoing upper GI bleeding (confirmed by performing upper GI endoscopy) and hemodynamic unstable patients, those with or coagulopathy refractory to correction; Of 77 patients, two patients in whom complete colonoscopy could not be performed were excluded from study.

Colonoscopy was performed in all cases with a standard colonoscope (CF150L; Olympus Optical Co., Ltd., Tokyo, Japan). After obtaining informed written consent, elective colonoscopy was performed following routine preparation (4–6 l of a polyethylene glycol-based purgative, administered orally beginning in the night prior to the procedure). Urgent colonoscopy was performed within 12–24 h of admission after rapid colonic preparation with a polyethylene glycol-based purgative either orally or by nasogastric tube (250 ml every 15 min); 4–6 l of purge were required for rapid and proper cleaning of the colon. The included patients

underwent total colonoscopy within 2 h after the clearance of stool and large clots.

They received Conscious sedation with pethidine and diazepam while monitoring Heart rate, blood pressure and oxygen saturation. The colonoscope was advanced up to the caecum and the terminal ileum was intubated when possible. The colon was carefully examined upon withdrawal with proper attention with washing of any obscured mucosa.

All procedures were done at the Gastroenterology unit, under Close senior supervision. The Colonoscopic evaluation was considered complete when the entire colonic mucosa was visualized. All endoscopic

abnormalities were noted and biopsies taken in suspected mass lesions.

Results

The study was conducted on 75 consecutive patients (49 males and 26 females) mean age 56 ± 6.3 years; range 39–67 years) with liver cirrhosis . 33 patients belong to child class A, 44 child class B.

The etiology of liver disease in the studied patients was Alcoholic in 43 (57.19%), hepatitis B in 6 (8%), Hepatitis C in 2(2.7%), cryptogenic in 15 (19.95%), NASH in 4 (5.3%), autoimmune hepatitis (AIH) in 4 (5.3%) and Budd- chiari Syndrome in 1(1.29%) patient (**Table – 1 to 4, Graph – 1, 2**).

Table – 1: Etiology.

Etiology	Present study (n-75)	Edmund J. Bini (n-437) [11]
Alcoholic	43(57.19%)	83(19%)
Cryptogenic	15(19.95%)	
Chronic Hepatitis B	6 (8%)	36(9%)
Autoimmune	4 (5.3%)	3(1%)
NASH related	4 (5.3%)	
Chronic Hepatis C	2 (2.7%)	225(52%)
BCS	1 (1.33%)	
Hemo chromatosis	0	4(1%)
Primary sclerosing cholangitis (PSC)	0	2(1%)

Table – 2: Gender.

Gender	PHC group (N-32)	Non PHC group (N-43)
Males	21	30
Females	11	13

Graph – 1: PHC prevalence.

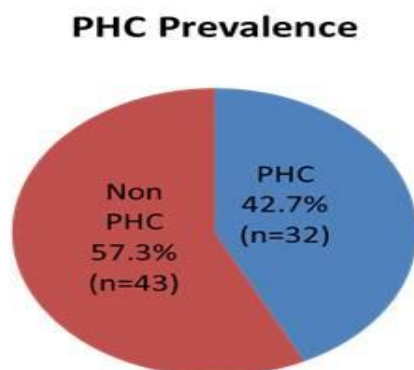


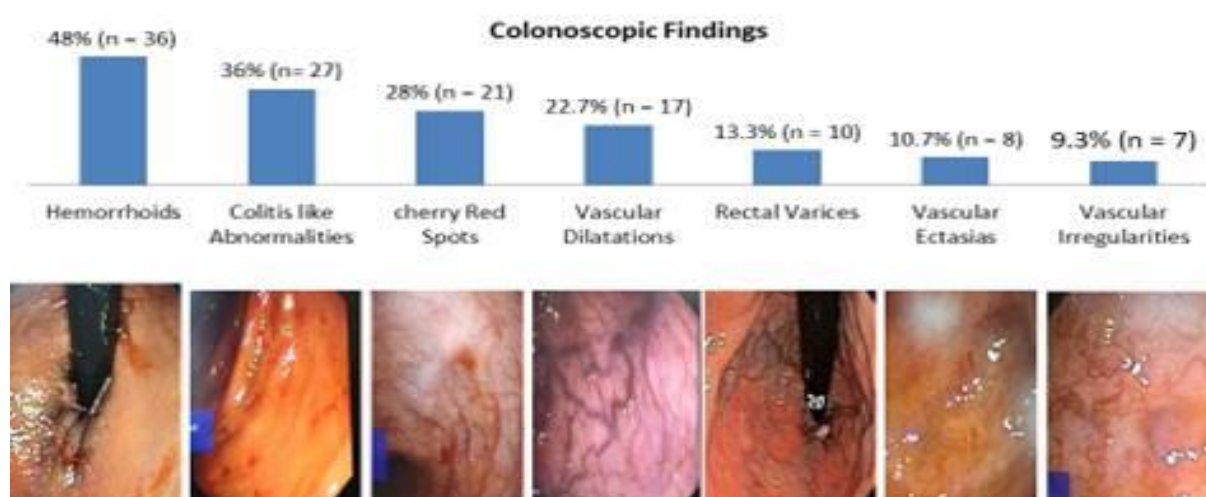
Table – 3: Comparison of PHC and non PHC groups.

Sl.no	Characteristic	PHC group(n=32)	Non PHC group(n=43)
1)	Mean Age	49 yrs	43 yrs
2)	Males	67.7%(n=21)	69%(n=30)
3)	h/o prior UGI bleed	62.5%(20)	30.23%(13)
4)	h/o prior EVL	44.1%(14)	19.3%(8)
5)	Esophageal varices grade 2 or more	59.3%(19)	20.9%(9)
6)	PHG	53.1%(17)	25.5%(11)
7)	Prior usage of NSBB	39.34%(13)	41.8%(18)
8)	CTP class C	53.12%(17)	25.5%(11)
9)	Mean Platelet count	59,000	81,000

Graph – 2: Spectrum of PHC and colonoscopic features in PHC.

Spectrum of PHC

- Most common abnormalities in PHC included Colitis like changes(diffuse erythema with mucosal edema) ,Vascular dilatation, Cherry red spots and Vascular ectasias.



When compared with the PHC-negative group regarding patients' age, sex, severity of hematochezia, positive family history and the history of intake of alcohol or non-steroidal anti-inflammatory drugs (NSAIDs), However, significant difference was seen when comparing both groups regarding the Child–Pugh class, prior history of GI bleeding who underwent

endoscopic procedures like endoscopic sclerotherapy (EST) or endoscopic variceal band ligation (EVL).

Grading of portal hypertensive colopathy (Table – 5)

Grade I: Erythema and edema of the colonic mucosa

Grade II: Erythema of colonic Mucosa with mosaic appearance **Grade III:** Vascular lesions of colon like Spots, telangiectasia, and angiodysplasia like lesions

Table – 4: Colonoscopic distribution of features of PHC.

	Caecum	As co	Tr col	Des co	Sig colon	Rectum
Diffuse red spots	1	1	1	13	7	21*
Vascular irregularities	0	1	1	2	2*	7
Vascular ectasia	1	1	2*	1	7	8
Vascular dilatation (visible vein)	0	0	0	0	1	17
Rectal varices	0	0	0	0	0	10
Hemorrhoids	0	0	0	0	0	42

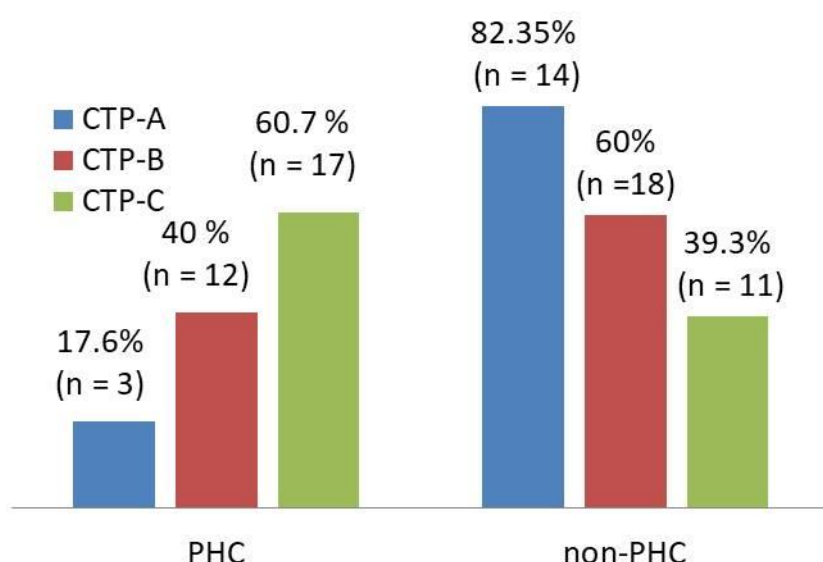
Table – 5: Grading of portal hypertensive colopathy.

Grading	Present study (n-72)
Grade I	15(46.8%)
Grade II	3(9.4%)
Grade III	14(43.8%)

Table – 6: Endoscopic findings of PHC in the studied groups.

Colonoscopy findings	Present study (n-72)	Edmund J. Bini (n-212) [11]	Yahia Z, et al. (n-32) [27]
Hemorrhoids	36(48%)	-	8(17.77%)
Colitis like	27(36%)	38%	-
Cherry red spots	21(28%)	-	19(59.36%)
Vascular dilatations	17(22.7%)	13%	9(28.13%)
Rectal varices	10(13.3%)	-	-
Vascular Ectasias	8(10.7%)	-	20(62.5%)
Vascular irregularities	7(9.3%)	-	22(68.75%)

Graph – 3: Correlation with Severity of liver disease.



Regarding the colonoscopic features of PHC, hemorrhoids were detected in 2/32 cases (6.25%) and vascular dilatation in 9/32 (28.12%) cases;

one of them had another lesion in the sigmoid colon. Diffuse red spots were detected in 19 cases (59.37%) of the studied patients and the

rectum was the most commonly affected region where they were the only source of rectal bleeding in four patients (12.5%). The descending colon was affected markedly by PHC in the form of vascular irregularities where they cause hematochezia in two patients (6.25%). Vascular ectasias were detected in the studied patients with PHC where the rectum was the most commonly affected region in 20 cases (65.5%). Hematochezia was due to bleeding vascular ectasia located in the transverse colon in one case only (3.12%) (**Table – 6**).

All the PHC-related sources of bleeding (7/32 cases (21.87%)) were successfully managed with argon plasma coagulation with no complications, using an argon gas flow at 1 l min⁻¹, at a power setting of 15–20W and forced mode' using the ERBE VIO 200D Argon beamer (ERBE Medical, Tubingen, Germany).

When compared with other studies, there were significant differences between the studied groups regarding the presence of hemorrhoids and rectal varices but no other differences regarding the other parameters.

Discussion

Bleeding per rectum is as common as upper GI bleeding and accounts for one fifth of hospitalizations. Moreover, it is the sixth most common symptom promoting an outpatient clinic visit, according to Shaheen, et al. [14]. Practical guidelines for evaluation of presumed rectal bleeding have been published [15, 16]. Evaluation of patients with rectal bleeding remains variable, and depends on the experience and the availability of methods of investigation and on the severity of bleeding.

Portal hypertension leads to hemodynamic disturbances throughout the GI tract. In the colon, colonic varices and PHC are well documented [17, 18].

In this study, endoscopic evaluation of cirrhotic patients with acute hematochezia revealed that

70 patients (90.9%) had bleeding sources that were not directly related to their liver condition, with a predominance of inflammatory lesions in 42 patients (54.54%), and only 7/77 patients (9.1%) bled due to PHC-related lesions. Correlation with Severity of liver disease was as per **Graph – 3**.

Our study revealed that the prevalence of PHC was increased with advanced liver disease as evidenced by worsening of the Child–Pugh class where more hemodynamic dysfunction is more.

Our study demonstrated that the prevalence of PHC is increased in patients who had undergone EVL and/or EST of esophageal varices. Previous studies have shown an increased prevalence of PHG following complete variceal obliteration by EST due to redistribution of the blood flow through the portal system, thereby increasing the pressure in the gastric mucosa resulting in the formation of vascular ectasias, cherry red spots and the mosaic pattern seen on endoscopy [19, 20].

Similarly, it would be suggested that PHC is related to portal pressure and that obliteration of the oesophageal varices may result in redistribution of the blood flow in similar ways in the stomach and the colon and the use of b-blockers would be protective against these regional changes [21, 22]. Rabinovitz, et al. [23] reported a 25.3% prevalence of hemorrhoids in 412 cirrhotic patients and ascribed this to the severity of portal hypertension and/or liver disease and Yamakado, et al. [24] considered hemorrhoids as an endoscopic feature of PHC. In the present work, hemorrhoids were more common in patients without PHC, a finding that may support suggestions claiming that hemorrhoids and/or colorectal varices would decompress the colonic portal venous system preventing the development of the PHC-related endoscopic changes.

Despite numerous studies, considerable controversies remain regarding the exact endoscopic appearance of PHC and inter-

observer variability has been reported. In the present study, vascular red spots, vascular irregularities and vascular ectasias were the most common features of PHC and the distal colon carried the main brunt. Therefore, complete colonoscopy is required, especially in the emergency setting, for detection of the widespread colonic vascular mucosal changes and may also visualise similar changes in the terminal ileum, termed 'portal hypertensive ileopathy [25, 26].

Conclusion

Our data revealed that PHC is not the only involved cause for hematochezia in cirrhotic patients despite their significant association. Instead, hemorrhoids and colitis like mucosal are also common. Severity of liver disease is an important factor in Management.

References

1. Sharma VK, Vasudeva R, Howden CW. Colorectal cancer screening and surveillance practices by primary care physicians: results of a national survey. *Am J Gastroenterol.*, 2000; 95(6): 1551–6.
2. Wauters H, Van Casteren V, Buntinx F. Rectal bleeding and colorectal cancer in general practice: diagnostic study. *BMJ*, 2000; 321(7267): 998–9.
3. Longstreth GF. Epidemiology and outcome of patients hospitalized with acute lower gastrointestinal hemorrhage: a population-based study. *Am J Gastroenterol.*, 1997; 92(3): 419–24.
4. Strate LL. Lower GI bleeding: epidemiology and diagnosis. *Gastroenterol Clin North Am.*, 2005; 34(4): 643–64.
5. Zuckerman GR, Trellis DR, Sherman TM, et al. An objective measure of stool color for differentiating upper from lower gastrointestinal bleeding. *Dig Dis Sci.*, 1995; 40(8): 1614–21.
6. Barnert J, Messmann H. Diagnosis and management of lower gastrointestinal bleeding. *Nat Rev Gastroenterol Hepatol.*, 2009; 6(11): 637–46.
7. Wong RF, Khosla R, Moore JG, et al. Consider colonoscopy for young patients with hematochezia. *J Fam Pract.*, 2004; 53(11): 879–84.
8. Barnert J, Messmann H. Management of lower gastrointestinal tract bleeding. *Best Pract Res Clin Gastroenterol.*, 2008; 22(2): 295–312.
9. Gostout CJ, Viggiano TR, Balm RK. Acute gastrointestinal bleeding from portal hypertensive gastropathy: prevalence and clinical features. *Am J Gastroenterol.*, 1993; 88(12): 2030–3.
10. Metcalf JV, Smith J, Jones R, et al. Incidence and causes of rectal bleeding in general practice as detected by colonoscopy. *Br J Gen Pract.*, 1996; 46(404): 161–4.
11. Bini EJ, Lascarides CE, Micale PL, et al. Mucosal abnormalities of the colon in patients with portal hypertension: an endoscopic study. *Gastrointest Endosc.*, 2000; 52(4): 511–6.
12. Weinshel E, Chen W, Falkenstein DB, et al. Hemorrhoids or rectal varices: defining the cause of massive rectal hemorrhage in patients with portal hypertension. *Gastroenterology*, 1986; 90(3): 744–7.
13. Baum S, Athanasoulis CA, Waltman AC, et al. Angiodysplasia of the right colon: a cause of gastrointestinal bleeding. *AJR Am J Roentgenol.*, 1977; 129(5).
14. Shaheen NJ, Hansen RA, Morgan DR, et al. The burden of gastrointestinal and liver diseases. *Am J Gastroenterol.*, 2006; 101(9): 2128–38.
15. Rogers BH. Endoscopic diagnosis and therapy of mucosal vascular abnormalities of the gastrointestinal tract occurring in elderly patients and associated with cardiac, vascular and

- pulmonary disease. *Gastrointest Endosc.*, 1980; 26(4): 134–8.
16. Zuccaro Jr G. Management of the adult patient with acute lower gastrointestinal bleeding. American College of Gastroenterology. Practice Parameters Committee. *Am J Gastroenterol.*, 1998; 93(8): 1202–8.
 17. Eisen GM, Dominitz JA, Faigel DO, et al. An annotated algorithmic approach to acute lower gastrointestinal bleeding. *Gastrointest Endosc.*, 2001; 53(7): 859–63.
 18. Papazian A, Braillon A, Dupas JL, et al. Portal hypertensive gastric mucosa: an endoscopic study. *Gut*, 1986; 27(10): 1199–203.
 19. Chen LS, Lin HC, Lee FY, et al. Portal hypertensive colopathy in patients with cirrhosis. *Scand J Gastroenterol.*, 1996; 31(5): 490–4.
 20. Sarin SK, Sreenivas DV, Lahoti D, et al. Factors influencing development of portal hypertensive gastropathy in patients with portal hypertension. *Gastroenterology*, 1992; 102(3): 994–9.
 21. Gupta R, Saraswat VA, Kumar M, et al. Frequency and factors influencing portal hypertensive gastropathy and duodenopathy in cirrhotic portal hypertension. *J Gastroenterol Hepatol.*, 1996; 11(8): 728–33.
 22. Hosking SW, Kennedy HJ, Seddon I, et al. The role of propranolol in congestive gastropathy of portal hypertension. *Hepatology*, 1987; 7(3): 437–41.
 23. Rabinovitz M, Schade RR, Dindzans VJ, et al. Colonic disease in cirrhosis. An endoscopic evaluation in 412 patients. *Gastroenterology*, 1990; 99.
 24. Yamakado S, Kanazawa H, Kobayashi M. Portal hypertensive colopathy: endoscopic findings and the relation to portal pressure. *Intern Med.*, 1995; 34(3): 153–7.
 25. Cales P, Zabotto B, Meskens C, et al. Gastroesophageal endoscopic features in cirrhosis. observer variability, interassociations and relationship to hepatic dysfunction. *Gastroenterology*, 1990; 98(1): 156–62.
 26. Misra SP, Dwivedi M, Misra V, et al. Ileal varices and portal hypertensive ileopathy in patients with cirrhosis and portal hypertension. *Gastrointest Endosc.*, 2004; 60(5): 778–83.
 27. Yahia Z., Gad A, Adel A., Zeid B. Portal hypertensive colopathy and haematochezia in cirrhotic patients: An endoscopic study. *Arab Journal of Gastroenterology*, 2011; 12: 184–188.