

# Percutaneous Closure of an Iatrogenic Aorta to Right Ventricle Fistula Acquired Following Intracardiac Repair

*Durgaprasad Rajasekhar, Velam Vanajakshamma and Kummaraganti Paramathma Ranganayakulu*

Iatrogenic aortocardiac fistulae have been described rarely following intracardiac repair. This 28 year-old-male presented to our facility with dyspnea going on 20 days after closure of ventricular septal defect (VSD) and resection of subaortic membrane. A communication was noticed between the aorta and the right ventricle (RV) upon transthoracic echocardiography. Cardiac catheterisation revealed a significant shunt and an aortogram revealed a 6 mm communication between aorta and right ventricle. Percutaneous closure of this defect was attempted under local anaesthesia through right femoral access. An alpha arteriovenous loop was formed despite repeated attempts, hence a retrograde approach for device delivery was considered. An 8 mm Amplatzer muscular VSD occluder device was deployed across the defect achieving a complete closure through an 8F delivery sheath. To the best of our knowledge this is the first report of an iatrogenic aorta to RV fistula occurring in a patient following an intracardiac repair which has been successfully treated percutaneously.

**Key Words:** Aortocardiac fistula • Aorto-RV fistula • Iatrogenic • Percutaneous intervention • Transcatheter closure

## INTRODUCTION

Fistulae between the aorta and cardiac cavities are rare entities which are usually seen following rupture of sinus of Valsalva aneurysms, as a complication of infective endocarditis and trauma. These have also been described following surgeries on aortic valves<sup>1,2</sup> and very rarely following repair of ventricular septal defects (VSD).<sup>3,4</sup> Though a redo cardiac surgery is the gold standard in treating an acquired iatrogenic aortocardiac fistulae, percutaneous interventions are emerging as a safe and attractive alternative when the patient refuses

redo surgery. We report this unique case of an acquired aorta to right ventricle (RV) fistula following an intracardiac repair for VSD along with resection of subaortic membrane where successful closure of this iatrogenic fistula could be achieved percutaneously.

## CASE REPORT

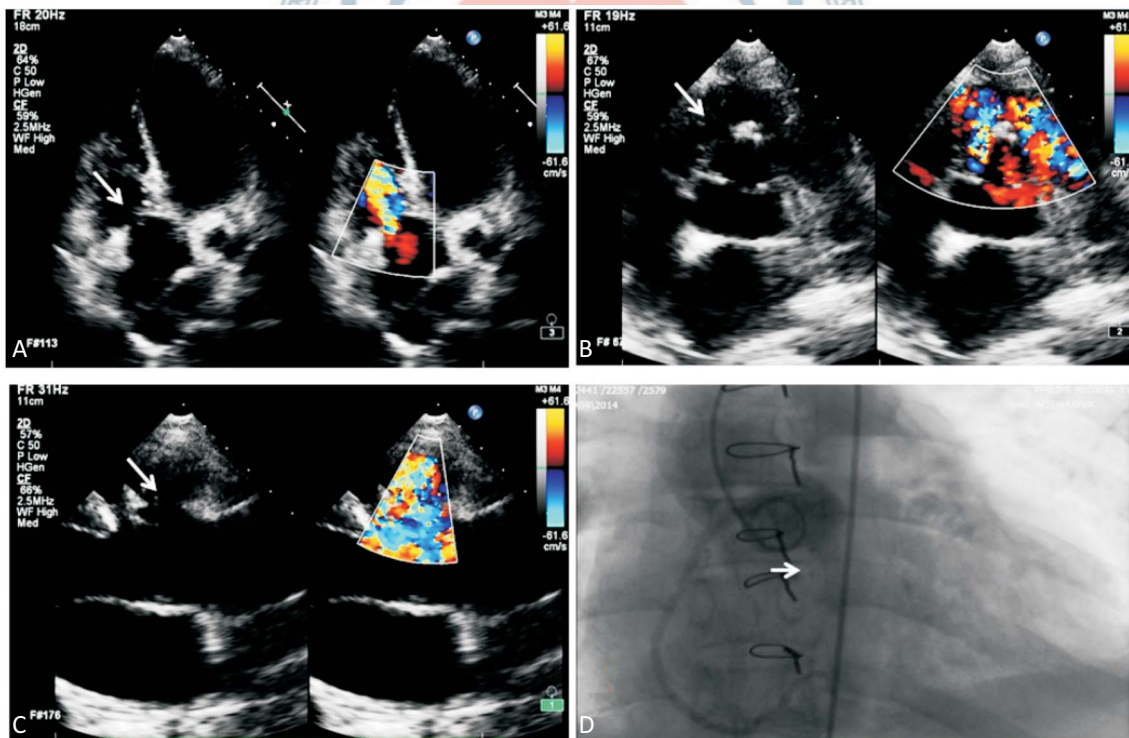
A twenty-eight year old farmer was diagnosed with 5 mm subpulmonic VSD with subaortic membrane for which surgical closure of VSD along with resection of subaortic membrane was done. He presented to us 20 days after surgery with dyspnea and palpitations of New York heart association class III. On examination he was afebrile, tachypneic and a continuous murmur of grade 4/6 was heard along the left parasternal region with maximum intensity over the 3<sup>rd</sup> and 4<sup>th</sup> left intercostal spaces.

Echocardiogram revealed an intact VSD patch with

Received: April 14, 2015 Accepted: July 1, 2015  
 Department of Cardiology, SVIMS, Tirupati, Andhra Pradesh, India.  
 Address correspondence and reprint requests to: Dr. D. Rajasekhar,  
 Department of Cardiology, Sri Venkateswara Institute of Medical  
 Sciences & University, Tirupati – 517507, Andhra Pradesh, India. Tel:  
 +91-9849221650; Fax: +91-877-2288133; E-mail: cardiologysvims@  
 gmail.com

no left ventricular outflow tract gradient. A communication was noticed between the right aortic sinus and RV (Figure 1A, B, C). Conventional aortogram with a 6F pigtail catheter was performed which revealed a 6 mm communication between the right aortic sinus and the RV (Figure 1D) with significant shunt ( $Q_p/Q_s = 1.8:1$ ) and with a systolic pulmonary artery pressure of 34 mm Hg. Therefore, device closure was attempted under local anaesthesia after obtaining appropriate informed consent. Right femoral arterial and venous accesses were achieved with 6F and 7F introducers. The entire procedure was done under fluoroscopy and transthoracic echocardiography (TTE) guidance. A 6F Judkins right catheter (Cordis Corporation, Miami Lakes, Florida, USA) was passed from the aortic side across the defect into RV using a hydrophilic guidewire 0.035 inch  $\times$  150 cm (Terumo Corporation, Tokyo, Japan). This was then exchanged over with a 0.035 inch  $\times$  260 cm hydrophilic exchange length guide wire (Terumo Corporation, Tokyo, Japan). The floppy end of the wire was delivered across the defect into the right ventricle and advanced into the

pulmonary artery, which was later snared through the right femoral vein with a 10 mm angled wire loop retriever (Cook Medical, Bjaeverskov, Denmark), forming a arteriovenous loop. An alpha loop was formed in the right ventricle despite repeated attempts, hence a retrograde approach was considered for device delivery to avoid entanglement of the tricuspid valve apparatus (Figure 2A). Over the wire, 8F Check-Flo Performer Introducer (Cook Medical, Bjaeverskov, Denmark) was introduced through right femoral arterial access and advanced. The wire was withdrawn once the sheath had crossed the defect. An 8 mm Amplatzer muscular VSD occluder device (AGA Medical, Plymouth, Minnesota, USA) with the delivery system was then advanced through the sheath. The disc on the RV side was initially released, and after confirming its position on TTE and fluoroscopy, the aortic end was delivered by further withdrawing the sheath (Figure 2B). The device was held in position across the defect for several minutes, and the electrocardiographic monitor was observed for conduction disturbances and ST-T changes. Prior to final re-



**Figure 1.** Iatrogenic communication between aorta (right coronary sinus) and right ventricle on 2D echocardiography and on aortogram. (A) Fistula (arrow) between aorta and right ventricle seen in apical 5 chamber view. (B) Fistula (arrow) between aorta (right coronary sinus) and right ventricle seen in parasternal short axis view. (C) Fistula (arrow) between aorta and right ventricle seen in parasternal long axis view. (D) Aortogram in AP view demonstrating a 6mm communication between aorta and right ventricle (arrow).

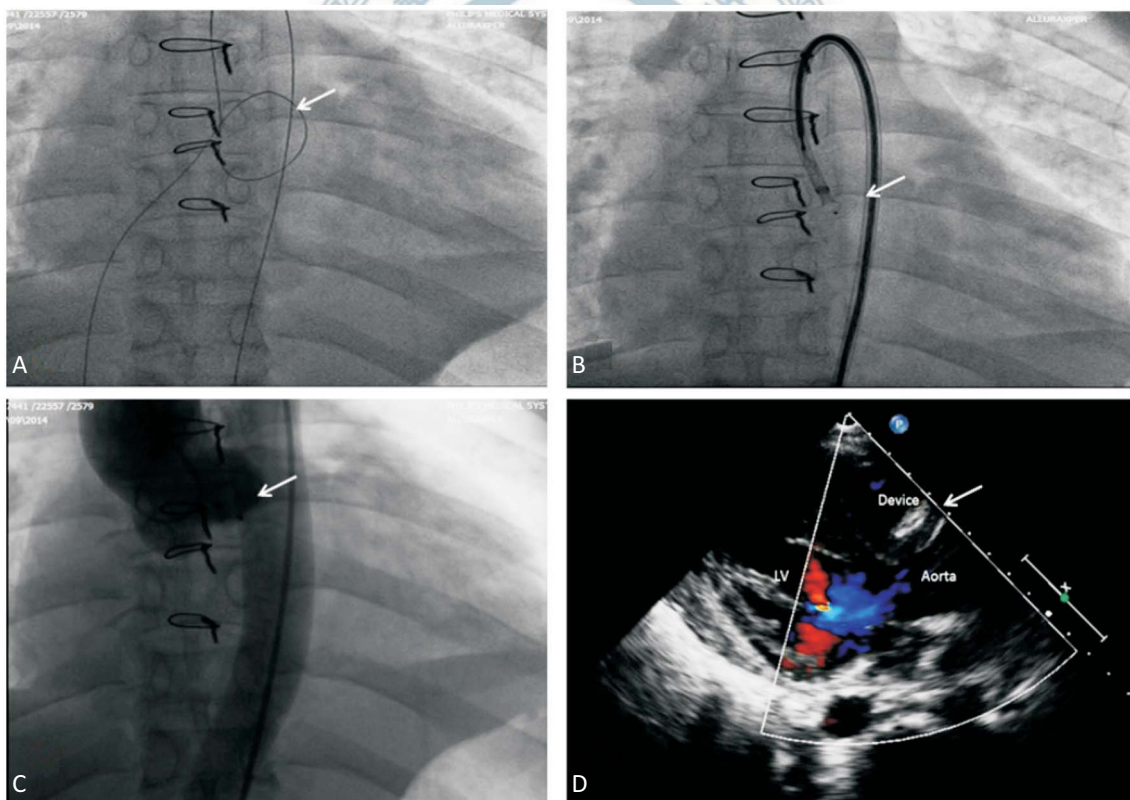
lease of the device, its position was confirmed by a hand injection accomplished through the delivery sheath and TTE. Repeat aortogram after the deployment of the device across the fistula revealed no residual leak across the device, no aortic regurgitation and good perfusion of the right coronary artery (Figure 2C). Repeat echo done post procedure and after 2 days revealed a satisfactory position of the occluder device with no residual leak across the defect (Figure 2D). Subsequently, the patient was discharged on dual antiplatelets. Three months later, routine follow-up indicated that the patient had no limitation of his routine activities, and repeat TTE revealed no residual leak across the defect.

## DISCUSSION

Iatrogenic aorto-RV fistulae have been described. Although surgery is the primary treatment option,

following surgery on aortic valve, but very rarely following repair of a high VSD. Inadvertent injury to the aortic sinus during resection of the subaortic membrane or repair of VSD or pseudoaneurysmal rupture could have been the likely cause for such a communication in our patient.

The high pressure gradient between the aorta and RV during the entire cardiac cycle causes an obvious continuous left to right shunt. This shunt, when large enough, can result in RV overload and congestive heart failure. The natural history of patients with iatrogenic aorta to RV fistula has not been well-studied, but Samuels et al.<sup>5</sup> studied the pathophysiology and natural history in patients with traumatic aorto-RV fistulae and reported that early diagnosis and prompt treatment are necessary to prevent development of congestive heart failure.



**Figure 2.** (A) Alpha arteriovenous loop (arrow) in view of which a retrograde approach was considered for device delivery. (B) Depicting 8 mm Amplatzer muscular ventricular septal defect (VSD) occluder device (arrow) positioned retrogradely across the aorto-right ventricular fistula seen in AP view. (C) Post procedure aortogram in AP view showing the Amplatzer muscular VSD occluder device (arrow) in position across the aorto-right ventricular fistula with no residual shunt. (D) Post procedure transthoracic echocardiography showing the Amplatzer muscular VSD occluder device in position across the aorto-right ventricular fistula with no residual shunt.

percutaneous treatments have emerged as an attractive alternative in these patients. Among the Amplatzer occluder devices, case reports of the Amplatzer duct occluder being used in aorto-RV fistulae acquired following aortic valve replacement exist.<sup>1,2</sup> An Amplatzer muscular VSD occlude device was used because this patient had a large defect (6 mm) with a thick waist which was retrogradely closed.

To the best of our knowledge this is the first report of iatrogenic aorta to RV fistula occurring in a patient following resection of subaortic membrane and repair of VSD which has been successfully treated percutaneously with an Amplatzer muscular VSD occluder device.

In conclusion, percutaneous closure of iatrogenic aorta-RV fistulae is a safe, cost effective treatment alternative to redo surgery, though a successful outcome is dependent on the anatomy of the defect.

#### CONFLICT OF INTEREST

None.

#### REFERENCES

1. Dussaillant GR, Romero L, Ramirez A, Sepulveda L. Successful percutaneous closure of paraprothetic aorto-right ventricular leak using the Amplatzer duct occluder. *Catheter Cardiovasc Interv* 2006;67:976-80.
2. Eng MH, Garcia JA, Hansgen A, et al. Percutaneous closure of a para-prothetic aorto-right ventricular fistula. *Int J Cardiol* 2007; 118:e31-4.
3. Matsushita T, Masuda S, Inoue T, Okawa Y. Perforation of sinus Valsalva 10 years after repair of ventricular septal defect. *Asian Cardiovasc Thorac Ann* 2012;20:353.
4. Gao L, Wu Q, Xu X, et al. Minimally invasive transthoracic device closure of an acquired sinus of Valsalva-right ventricle fistula in a pediatric patient. *Iran J Pediatr* 2014;24:327-30.
5. Samuels LE, Kaufman MS, Rodriguez-Vega J, et al. Diagnosis and management of traumatic aorto-right ventricular fistulas. *Ann Thorac Surg* 1998;65:288-92.

