



ORIGINAL RESEARCH PAPER

Orthopaedics

"UTILITY OF VAC – IN VARIOUS SURGICAL CONDITIONS"

KEY WORDS:

Dr. NVS Vinay

3rd year junior resident, King George Hospital

Dr. V Dharma Rao*

Prof & HOD Department of Orthopaedics, King George Hospital, Visakhapatnam .
*Corresponding Author

ABSTRACT

Large, complicated wounds pose a significant surgical problem. Negative pressure wound therapy is one of several methods that helps to obtain better results in case of open infected wounds by reducing the bacterial burden and causing wound shrinkage. We have conducted a prospective interventional study on various conditions where VAC(vacuum assisted closure) can be used. All these conditions have been successfully treated by use of VAC.

INTRODUCTION

Wound management is still a surgical challenge. Its utility was initially described by MORYKWAŚ et al in 1997. Fleischmann et al in 1993, 1st described Role of VAC THERAPY in wound management. Morykwas MJ et al , in 1993 reported that NPWT decreases bacterial colonization in open wounds. Certain indications include Acute and traumatic wounds, infected wounds, pressure ulcers, amputated stumps, infected implants, exposed bones, chronic ulcers, flaps, grafts and wound dehiscence.

MATERIALS AND METHODS

The cases presented in this study are those who were admitted as inpatients at King George General Hospital –Andhra medical college from may 2017 to january 2018. All patients were studied and clinical findings were recorded as per the proforma case sheet. All cases were followed up to discharge. (1 week-4weeks).

INCLUSION CRITERIA –

- Infected amputated stumps
- Bed sores
- Chronic ulcers
- Infected implants
- Open injuries

EXCLUSION CRITERIA-

- Malignancy
- Raw area over exposed vessels and nerves.
- Patients not willing for VAC therapy.
- Chronic osteomyelitis
- Eschar.

MATERIALS USED IN VAC

The dressing material utilized was medium density polyvinyl alcohol (PVC) sponge. The pore size ranged between 300 – 600 U and is an open cell type of sponge.



Figure 1: PVC SPONGE

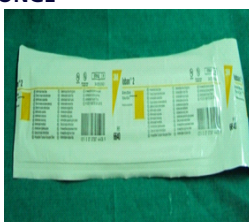

Figure 2: ADHESIVE DRAPE

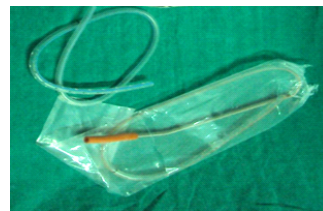

Figure 3: SUCTION TUBE

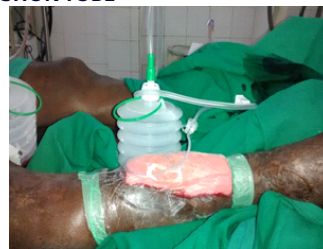

Figure 4: SUCTION DRAIN

PROCEDURE - After thorough debridement. The size of wound is documented. Cut the sponge in required size and shape. Place it over the wound, seal it with adhesive drape after introducing the suction tube.

PRESSURE: In our study intermittent pressure was applied every 30 minutes

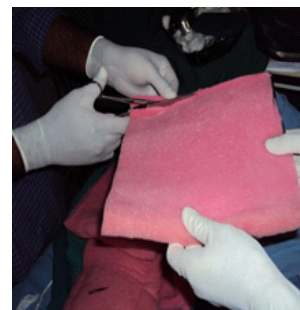


Figure 5

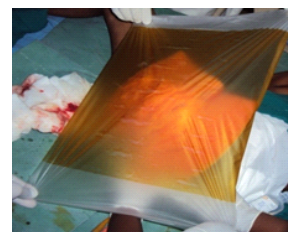


Figure 6 Post vac measurement of wound size

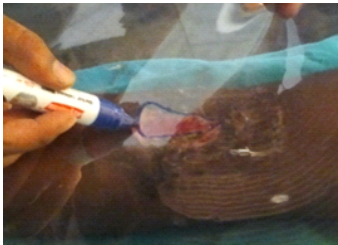


Figure 7

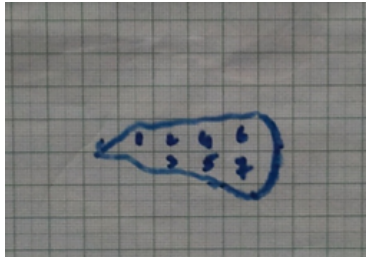


Figure 8: Plotting Wound Size

In our study VAC dressing was applied for 4 days (5 cases, 40%), 6 days (4 cases, 34%), 7 days (2 cases, 13%), 14 days (1 cases, 08%).

Depending on -size of the wound, infection , comorbidity

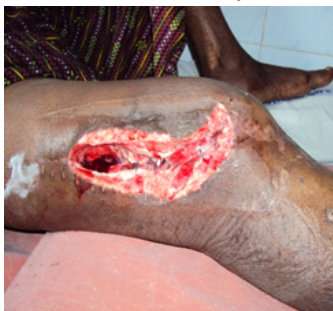

Figure 9: Post Operative Wound Infection

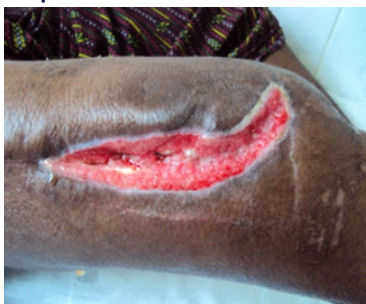

Figure 10: wound after VAC application

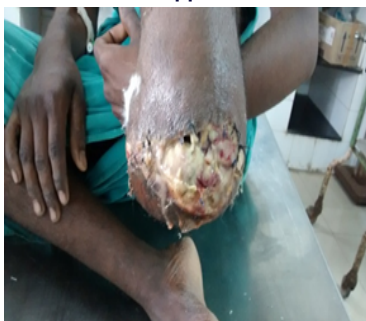

Figure 11: infected amputated stump

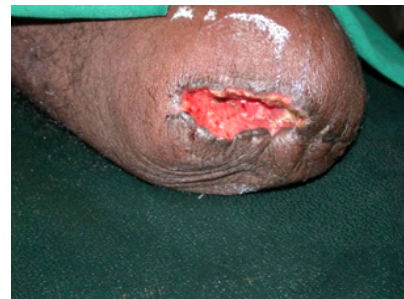

Figure 12 : post VAC

RESULTS

12 patients age between 12-60 years of age group treated with VAC therapy. 4 patients are with co morbities (diabetes mellitus). The mean age group was 40.4 yrs. 7 males and 5 females are included in the study. Mean wound size was 66 cm² before the application of VAC dressing which reduced to a mean of 36 cm² at the completion of VAC therapy.

COMPLICATIONS

include pain, infection with anaerobes, fluid depletion. These complications have not been encountered in the study.

DISCUSSION

Negative pressure wound dressing was initially introduced in the management of subacute and chronic wounds. With encouraging results, the scope of VAC is increasing .VAC facilitates fluid removal from the wound and by increasing angiogenesis and helps granulation tissue formation. It also reduces bacterial counts and reduces cross infection. MICRODEFORMATION and MACRODEFORMATION, occurs in tissues both of which facilitates wound healing.

CONCLUSION

VAC has been proven to be a reliable method of treating a variety wounds.It greatly increases the rate of granulation tissue formation and lowers bacterial counts to accelerate wound healing. It can be used as a temporary dressing to prepare wounds optimally prior to closure or as a definitive treatment for nonsurgical and surgical wounds and is well tolerated with few complications or contraindications and is playing an ever-expanding role in wound care. The limitation of this study is that this was a single-arm, prospective, observational study with no control group.

REFERENCES

1. Jerome D : Advances in negative pressure wound therapy: the VAC instill. J Wound Ostomy Continence Nurs 2007; 34 (2): 191-94.
2. Hunter JE, Teot L, Horch R et al: Evidence based medicine: vacuum assisted closure in wound care management. Int Wound J 2007;4(3):256-69.
3. Kumar P. Limited Access Dressing. Wounds. 2008; 20: 49-59.
4. Moues CM, Vos MC, Bemd GJ van den et al: bacterial load in relation to vacuum assisted closure wound therapy: a prospective randomised trial. Wound Repair Regen 2004; 12: 11-17.
5. Mullner T, Mrkonjic L, Kwasny O et al: The use of negative pressure to promote the healing of tissue defects: a clinical trial using the vacuum sealing technique. Br J Plast Surg 1997; 50: 194-99.
6. SCresti S, Ouaisi M, Sielenzoeff I et al: advantage of Vacuum assisted closure on healing of wound associated with omentoplasty after abdominoperineal excision: a case report. World J Surg Oncol 2008; 6: 136.