

See discussions, stats, and author profiles for this publication at: <https://www.researchgate.net/publication/283123013>

Cysticercosis – Is It a Pathological or Radiological Diagnosis?

Article in *International Journal of TROPICAL DISEASE & Health* · October 2015

DOI: 10.9734/IJTDH/2016/20362

CITATIONS

0

READS

76

4 authors, including:



Sandeep Bansal

Postgraduate Institute of Medical Education and Research

78 PUBLICATIONS 459 CITATIONS

[SEE PROFILE](#)



Ramandeep Singh Virk

Postgraduate Institute of Medical Education and Research

99 PUBLICATIONS 285 CITATIONS

[SEE PROFILE](#)



Alok Rathi

University Hospitals Birmingham NHS Foundation Trust

8 PUBLICATIONS 10 CITATIONS

[SEE PROFILE](#)

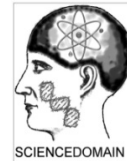
Some of the authors of this publication are also working on these related projects:



Traumatic optic neuropathy [View project](#)



PEDIATRIC CAROTID BODY PARAGANGLIOMA [View project](#)



Cysticercosis – Is It a Pathological or Radiological Diagnosis?

Bansal Sandeep^{1*}, Virk Ramandeep¹, Rathi Alok¹ and Ashok K. Gupta¹

¹Department of Otolaryngology and HNS, PGIMER, Chandigarh, India.

Authors' contributions

This work was carried out in collaboration between all authors. Author BS did the study design and wrote the protocol. Authors VR and RA did the statistical analysis and literature searches while analyses of study was by author AKG. All authors read and approved the final manuscript.

Article Information

DOI: 10.9734/IJTDH/2016/20362

Editor(s):

- (1).
- (2).

Reviewers:

- (1).
- (2).
- (3).
- (4).
- (5).

Complete Peer review History:

Case Study

Received 24th July 2015
Accepted 28th September 2015
Published 24th October 2015

ABSTRACT

Cysticercosis is one of the major neglected tropical diseases with increasing incidence recently. Adequate diagnosis is required for treatment of this eradicable disease. We report two cases of cheek swellings diagnosed as cysticercosis with differences in investigation modality used. While fine needle aspiration biopsy may help in definite diagnosis, site of lesion may not be appropriate. Ultrasonography on contrary can provide site accurately and help clinician in definite diagnosis. Thus clinician must select the modality appropriately according to feasibility and site of lesion.

Keywords: Cysticercosis; FNAC; MRI; ultrasonography; cheek.

1. INTRODUCTION

Cysticercosis caused by *Taenia solium* larva is a modern day plague found worldwide [1].

Endemicity has been demonstrated in areas of pork consumption, poor hygiene and low socio-economic conditions. The morbidity and mortality is high due to hidden disease and late diagnosis

*Corresponding author: Email: drsandeepb@rediffmail.com;

[1]. Diagnosis of this eradicable disease requires precise investigations. We here report two cases with diagnostic challenges.

2. CASE 1

A 12 year-old male child presented with painful swelling in right cheek since one week. His medical history was non contributory. On examination a three x two cm firm tender swelling was noted in right cheek with well defined margins and restricted mobility. Oral cavity examination and other ear, nose and throat (ENT) examination were within normal limits. General body examination showed no palpable swelling. Ultrasonography (USG) was done to reveal a well defined cystic swelling with eccentric scolex diagnostic of cysticercosis (Fig. 1).

3. CASE 2

A 30 year-old asymptomatic female presented by swelling in left cheek since one week. Her medical history was non contributory. On examination a two x two cm firm mobile non-tender swelling was noted in pre-auricular region. Oral cavity, ENT and systemic examination were within normal limits. Fine needle aspiration cytology (FNAC) was done to reveal presence of tegmental layer of larva confirming cysticercosis of parotid. Gadolinium enhanced magnetic

resonance imaging (MRI) showed no cranial lesion, but cheek lesion was present in masseter suggestive of myocysticercosis (Fig. 2).

Both the patients received Albendazole at 15 mg/kg body weight for one month and were free of disease on follow up. Child also received dexamethasone 8 mg tapered over two weeks.

4. DISCUSSION

Cysticercosis is one of the major neglected tropical diseases disseminated worldwide due to increased immigration and travel [1,2]. It is recently reported to cause hospitalization rate of 8.03 per million population with case fatality rate of 1.4% [3]. Soft tissue cysticercosis is known to be present in 54% of infected people, though neurocysticercosis presents more to the clinician [4].

Human beings, both definitive and intermediate hosts, may accidentally or incidentally become the host of parasite in three ways: Faecal-oral infection, faecal-oral autoinfection and internal autoinfection. These eggs are partially digested in the stomach, evolve into oncospheres to penetrate the small intestinal mucosa and disseminate throughout the body eventually forming cyst [5]. An asymptomatic, isolated cyst may remain undetected, until it enlarges, migrates or dies and produces symptoms.

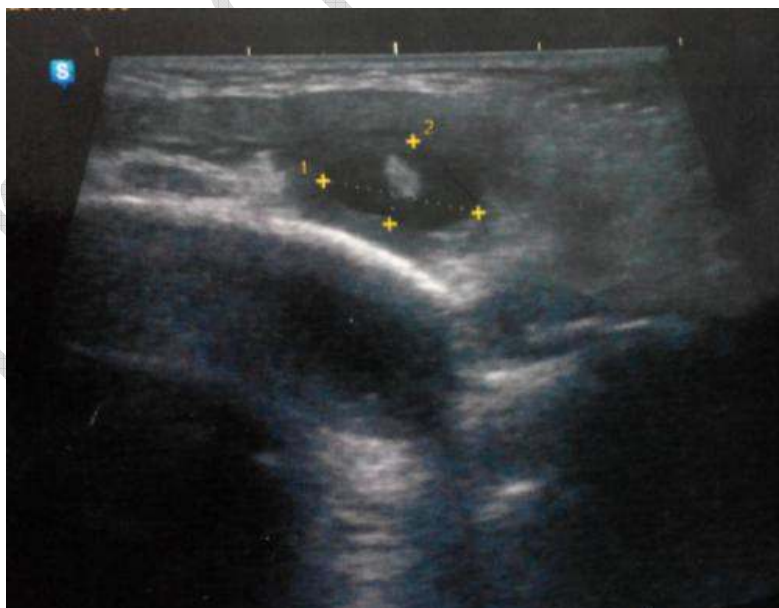

Fig. 1. High frequency sonography of right cheek showing cystic lesion with eccentric scolex diagnostic of cysticercosis

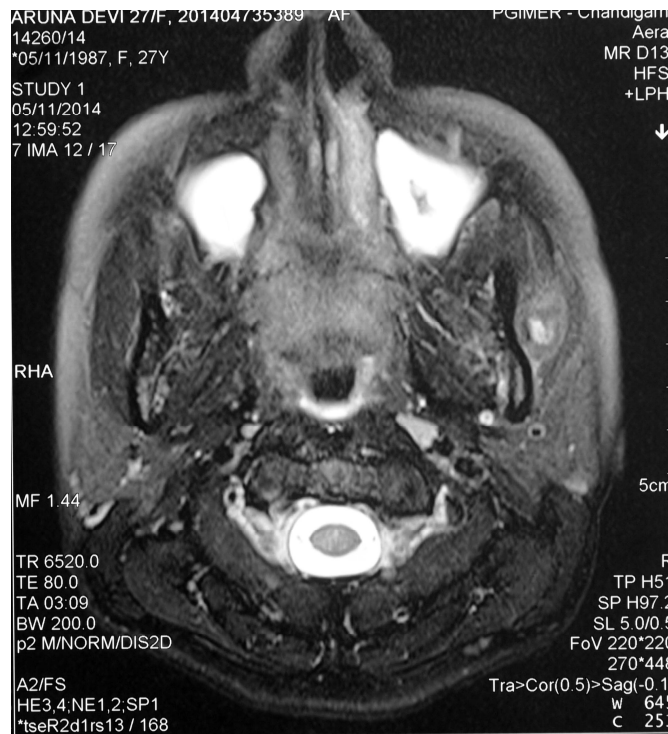

Fig. 2. CEMRI of left masseter showing heterogenous lesion with central cystic component and peripheral enhancement

Head and neck is second most common site for cysticercosis, presenting as subcutaneous nodules [6]. It forms the differential diagnosis of any soft-firm swelling for an otolaryngologist including lipomas, neurofibromas, lymphadenopathy in neck, mucous retention cyst, fibroma, leiomyoma, dermoid cyst, lipoma or a benign lesion of salivary gland or neural origin in oral cavity, acute parotitis, parotid abscess, parotid sialadenitis, subcutaneous tissue abscess, pyomyositis or lymphadenitis in cheek [7,8].

Such clinical scenario increases the dilemma for high yielding investigation, complicated further by variations in host-body reactions and stage of disease evolution. With economic constraints, as this disease is endemic in resource limited places, next investigation is usually FNAC or sonography. Possibility of definitive diagnosis by identification of larva has made the FNAC as first investigation in skin nodules though it has less sensitivity (46.4% to 94.2%) [6,8]. Sonography is the investigation of choice in any soft tissue swelling. Human cysticercosis can be diagnosed reliably with demonstration of scolex in the lesion, sensitivity and specificity of which depends on expertise, thorough scanning, and stage of disease [9].

Using serological methods, sensitivity of antibody testing tends to be high for cases with multiple cysts (94%) than single or calcified cysts (28%). Further, false positive with prior exposure to *T. solium* antigens can occur [5].

Radiology is the investigation of choice if resources are available and affordable. Computed tomography/MRI has been used for diagnosis with demonstration of scolex. Role of CT in neurocysticercosis is well known and characteristic or suggestive features on MRI are respectively absolute or major criteria of Del Bretto et al. for diagnosis. Starry sky appearance is seen in disseminated cysticercosis on MRI [10,11]. Cysts are peculiarly oriented in direction of muscle fibres. Rather than absolute, more often radiology is suggestive of cysticercosis and forms one of the major diagnostic criteria, but histological examination gives the definitive diagnosis.

We had two such cases which underline the importance of investigation modality as diagnosis changes accordingly. While FNAC was initial investigation in view of benign neoplasia, sonography was done in view of acute inflammatory disorder. FNAC did confirm

cysticercosis, though, pathologist reported it as parotid lesion. This changed to myocysticercosis of masseter with MRI. Such possibilities add another horizon of diagnostic dilemma. Importance of accurate diagnosis lies in definite management and disease eradication.

5. CONCLUSION

Cysticercosis can be accurately diagnosed with easily available low cost investigations. Clinicians should choose appropriate modality with low threshold especially in endemic areas. While definite diagnosis can only be made by demonstration of larva, we suggest a compulsory radiological investigation in cysticercosis unless site is proven by other method.

CONSENT

It is not applicable.

ETHICAL APPROVAL

It is not applicable.

COMPETING INTERESTS

Authors have declared that no competing interests exist.

REFERENCES

1. Brown WJ, Voge M. Cysticercosis. A modern day plague. *Pediatr Clin North Am.* 1985;32(4):953-69.
2. Who.int [Internet]. Report of the WHO expert consultation on foodborne trematode infections and taeniasis / cysticercosis. Vientiane, Lao People's Democratic Republic; 2009. Available:http://apps.who.int/iris/bitstream/10665/75209/1/WHO_HTM_NTD_PCT_2011.3_eng.pdf (Accessed on 30.11.2014)
3. Who.int [Internet]. Taeniasis/Cysticercosis, Fact Sheets, Media Centre, WHO. Available:<http://www.who.int/mediacentre/factsheets/fs376/en/> (Accessed on 30.11.2014).
4. O'Keefe KA, Eberhard ML, Shafir SC, Wilkins P, Ash LR, Sorvillo FJ. Cysticercosis-related hospitalizations in the United States, 1998-2011. *The American Journal of Tropical Medicine and Hygiene*; 2014. DOI: 10.4269/ajtmh.14-0506
5. Dixon HBF, Lipscomb FM. Cysticercosis: An analysis and follow-up of 450 cases. *Proceedings of the Royal Society of Medicine.* 1962;55:242.
6. Baily G, Garcia HH. Other cestode infections. In: Farrar J, Hotez PJ, Junghanss T, Kang G, Lalloo D, White NJ, editors. *Manson's Tropical Diseases*, 23rd ed. Oxford: Elsevier Saunders. 2014; 820-832.e1.
7. Tewari S, Singh S, Jaiswal V, Mishra AK. Myoparasitism mimicking parotid swelling: A rare presentation of cysticercosis. *BMJ case reports* 2014; 2014.
8. Handa U, Garg S, Mohan H. Fine needle aspiration in the diagnosis of subcutaneous cysticercosis. *Diagnostic cytopathology.* 2008;36:183-7.
9. Kala P, Khare P. Fine-needle aspiration cytology as a diagnostic modality for cysticercosis: A clinicocytological study of 137 cases. *Journal of cytology / Indian Academy of Cytologists.* 2014;31:68-72.
10. Vijayaraghavan SB. Sonographic appearances in cysticercosis. *Journal of Ultrasound in Medicine: Official Journal of the American Institute of Ultrasound in Medicine.* 2004;23:423-7.
11. Jankharia BG, Chavhan GB, Krishnan P, Jankharia B. MRI and ultrasound in solitary muscular and soft tissue cysticercosis. *Skeletal radiology.* 2005;34:722-6.

© 2016 Sandeep et al.; This is an Open Access article distributed under the terms of the Creative Commons Attribution License (<http://creativecommons.org/licenses/by/4.0>), which permits unrestricted use, distribution, and reproduction in any medium, provided the original work is properly cited.

Peer-review history:

The peer review history for this paper can be accessed here:
<http://sciedomain.org/review-history/11973>