

Patho-anatomy and Patho-mechanics of Glenohumeral Instability

Sagar Vivek Kakatkar^{1,2}, Jonathan Herald¹

Abstract

Patho-anatomy and patho-mechanics form the basis of management of any pathology. Gleno-humeral joint is one of the most functionally complex joint in the body because of its greater range of motion and interrelationship of the forces acting on the joint. All these factors should be considered when planning the management of the glenohumeral instability since inability to address anatomical deficiencies may lead to failure; which may further complicate the treatment. The static and dynamic stabilizers of the glenohumeral joint have been described here in relation to the shoulder instability.

Keywords: Glenohumeral instability, pathoanatomy, pathomechanics, inferior glenohumeral ligament

Introduction

A thorough understanding of pathoanatomy and pathomechanics of the glenohumeral joint is an integral part of managing patients with glenohumeral instability. Ever since the description of pathophysiology of shoulder dislocation by Hippocrates in the year 460-377 BC, extensive research has been done to understand this common pathology. The management principles for an unstable shoulder focus on reestablishing the glenohumeral anatomy to near normal state to prevent further episodes of instability. Author has made an effort to give an overview of the pathoanatomy and pathomechanics of the glenohumeral instability.

Glenohumeral Stabilizers and Respective Pathologies:

Shoulder being the most dynamic joint in the body, is inherently unstable. To discuss the deviations from the normal anatomy, knowledge of these stabilizers is important

(Table 1).

All the static stabilizers are the ones which are primarily responsible for the glenohumeral stability, and the dynamic stabilizers act as assistive glenohumeral stabilizers. The assistive stabilizers may be primarily or secondarily involved in glenohumeral instability and treating their pathologies may or may not improve the glenohumeral stability.

A. Articular anatomy and pathoanatomy:

- To allow 6 degrees of freedom at the glenohumeral joint i.e. three rotations and three translations, the glenohumeral articulation is the least constrained one.
- The relationship of humeral head with the glenoid is compared to a Golf ball on a tee as the humeral head surface area is three times greater than the glenoid surface area [1,2]. At any anatomical position of the joint, only 25%-30% of the humeral head is in contact with the glenoid surface [1,2,3]. Hence, this area of the humeral head and the part of the glenoid in contact with the head at a certain

position of the joint is the only bony restraint to the translation at that position.

- Apart from the articular surface pathologies, abnormal humeral and glenoid versions also predispose to glenohumeral instabilities.
- Hence, osseous defects of glenoid and humeral head if present can be major predisposing factors for recurrent glenohumeral instabilities.

1. Glenoid osseous defects:

- Osseous defects of glenoid in recurrent dislocations are very frequent. Study done by Sugaya et al. [4] in recurrent anterior shoulder dislocations suggested that 90% of the shoulders had bony deficiencies of glenoid, of which 50% were fragment type defects whereas 40% had erosive type defects.
- Initially the glenoid defects were thought to be anteroinferior, but actually these glenoid defects are situated anteriorly relative to glenoid since the glenoid is inclined anteriorly in sagittal plane [5].
- The osseous defects of the glenoid typically lead to mid-range instability since the mid-range shoulder motion is grossly dependent on glenoid concavity and dynamic compressive force generated by rotator cuff muscle group.
- Many anatomical, biomechanical, and radiological studies have been done to check the critical size of the glenoid defects. Loss of >50% of the glenoid width can lead to up to 30% loss of resistance for translation [6], and osseous defect with 21% or more loss of glenoid length can lead to

¹Vivaan Clinic, Nashik, Maharashtra, India,

²Dr. VPMCH, Nashik, Maharashtra, India,

³Orthoclinic, Sydney, Australia.

Address of Correspondence:

Vivaan Clinic, First floor, N.S.B. center, Canada Corner, Nashik

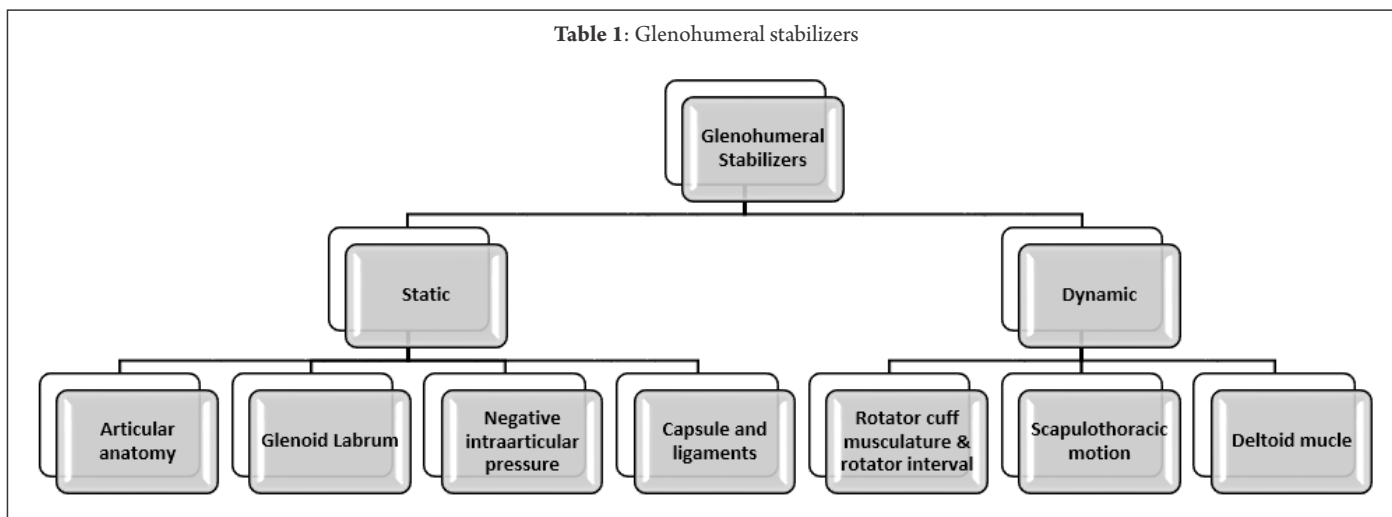
Email: drsagarkakatkar@gmail.com



Dr. Sagar Kakatkar



Dr. Jonathan Herald

Table 1: Glenohumeral stabilizers

recurrent instability [7]. While Lo et al. [8] had quantified the critical defect as the one which measures 25-27% of the inferior glenoid width, this value is approximately equal to 21% of the glenoid length, and several biomechanical studies have compared these two measurement techniques for the glenoid bone defects [7].

2. Humeral osseous defects:

- Initial few studies mentioned that Hill-Sachs lesions which involve 20-25% of the humeral head area lead to symptomatic instability and require active surgical intervention for the same [9,10].
- However, several studies have shown that the size of the Hill-Sachs lesion relative to the glenoid is more important than the absolute size of the Hill-Sachs lesion (Fig. 1).
- Burkhart and De Beer [11] described the concept of engaging and non-engaging Hill-Sachs lesions. Engaging Hill-Sachs are the symptomatic Hill-Sachs lesion which can be considered critical Hill-Sachs lesions. These lesions are the ones which lie medial to the glenoid track.
- Glenoid track is the area of the humerus in contact with the glenoid during functional range of motion of the shoulder. The Hill-Sachs lesion which remains within the glenoid track has no risk of engaging at the anterior glenoid rim (Fig. 2).

B. Glenoid labrum:

- Glenoid labrum is a fibrocartilaginous structure which helps in glenohumeral stability in two ways: mechanical block

effect and contribution in maintaining the negative intra-articular pressure.

- Mechanical effect of the glenoid labrum is comparable to “Chock Block” which is used to prevent a car wheel from rolling downhill. It helps by increasing the concavity of the glenoid.
- Superior labrum is thought to have minimal effect on glenohumeral stability, but studies such as that done by Rodosky et al. [12] showed that superior labrum detachment decreases resistance to torsional force acting on the humerus and secondarily leads to excessive strain on inferior glenohumeral ligament (IGHL), thus contributing to anteroposterior instability.
- Lippitt et al. [13] described the stability ratio as the force necessary to dislocate the humeral head from the glenoid divided by compressive load. This ratio is more for greater glenoid concavity and decreased with excision of glenoid labrum by almost 20%. Halder et al. [14] described the stability ratio with or without the labrum in anteroposterior and superoinferior direction. According to this study, the average contribution of the glenoid labrum in the glenohumeral stability was 10%.
- Several studies have emphasized importance of glenoid labrum in maintaining the negative pressure effect. Although not studied in details, this effect of the glenoid labrum does carry biomechanical significance. Biomechanical study which compared the fixation of torn labrum at the glenoid rim and

fixation of the labrum just medial to the rim creating a “Bumper” effect showed that the “Bumper effect” after the Bankart repair which is often been discussed does not increase translational stability of the glenohumeral joint [15]. This might be attributed to inability to restore the negative articular pressure post labral repair.

C. Negative intra-articular pressure:

- The dynamic rotator cuff contraction-compression mechanism, glenoid labrum, glenoid concavity, etc., all play a major role in maintaining the negative intra-articular pressure (Fig. 3).

D. Capsule and ligaments:

- Shoulder joint capsule has several thickenings and these folds are the “glenohumeral ligaments.” Of the three glenohumeral ligaments, primarily IGHL

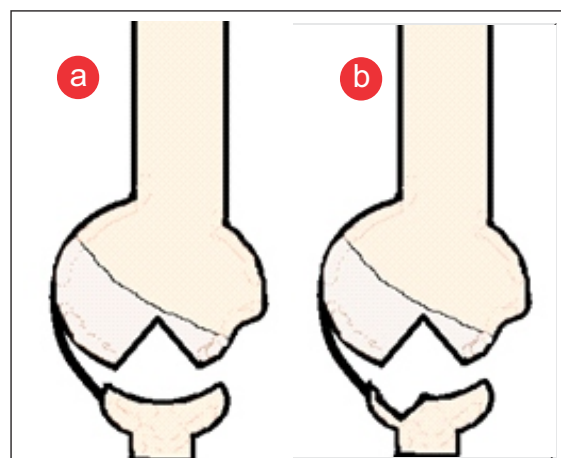
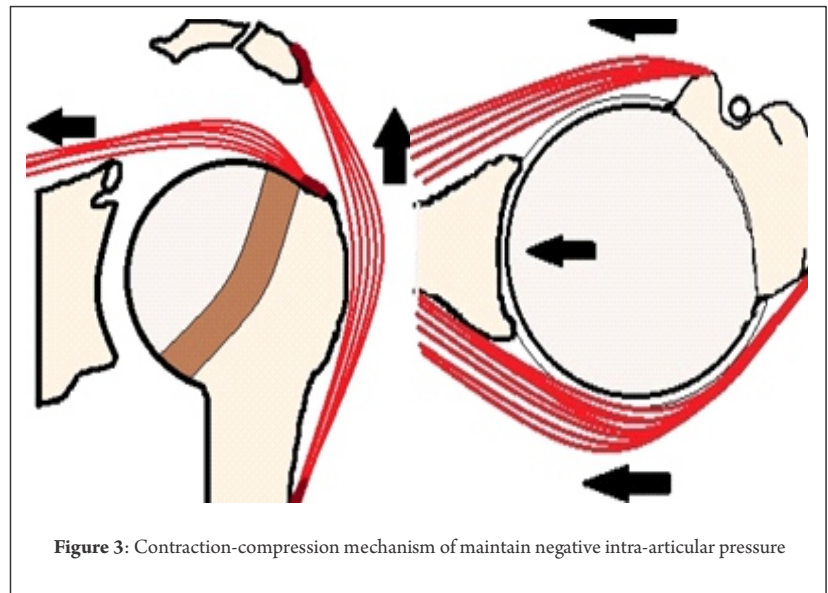
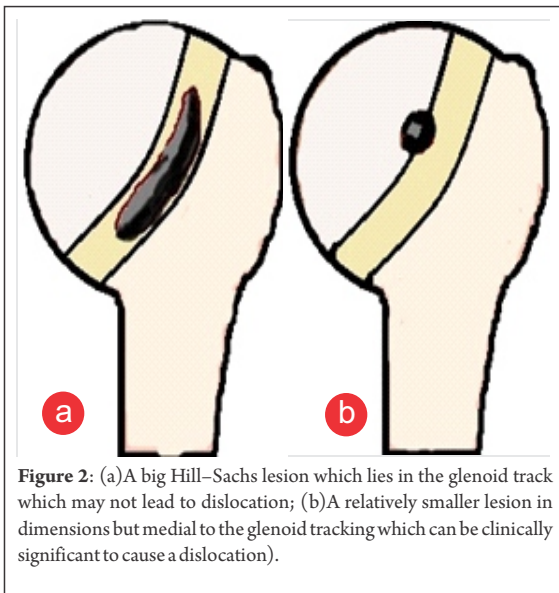


Figure 1: (a and b) Hill-Sachs lesion dimensions should be considered together with the glenoid defect dimensions. The same sized Hill-Sachs defect may become clinically significant in cases of associated glenoid defects.



anterior and posterior limbs play an important role in the shoulder stabilization. Capsulolabral complex of the IGHL is most often injured in cases of instability.

- The IGHL glenoid side geometry has been described in two ways:
 1. O'Brien et al. [16]: Two thick anterior and posterior bands of IGHL capsulolabral complex exist. Of these two, anterior band is thicker and posterior band is inconsistently found in only 63% or fewer cases [17,18,19].
 2. Bigliani et al. [20,21]: Three regions of IGH complex; superior band, anterior axillary pouch, and posterior axillary pouch have been described.
- IGHL also has two types of insertional attachment geometries on the humeral side: split type (58%) and broad type (42%). Knowledge of the two types is important in the management of glenohumeral instabilities since failure to release any of the folds of IGHL may lead to inaccurate capsulorrhaphy [22].
- The proprioceptive mechanoreceptors such as Pacinian corpuscles and Ruffini endings exist in shoulder capsule which are extremely sensitive to the range of motion and pressure sense which may occur in glenohumeral translation. Stimulation of these receptors further leads to adaptive contractions of the muscles around the shoulder, thus contributing to the stability. Studies done by Warner et al. [23] and Lephart et al. [24] have suggested that the proprioception is disturbed in patients with instability and is improved after stabilization

surgery [25,26].

E. Rotator Cuff and rotator interval:

- Since rotator cuff is important for the concavity-compression mechanism of shoulder stability, deficiencies of the rotator cuff; mainly the retracted, massive cuff tears contribute to the glenohumeral instabilities (Fig. 3).
- The rotator interval on other side has coracoid at the base, supraspinatus, and subscapularis which are convergent at the apex. Superior glenohumeral ligament (SGHL) and coracohumeral ligament traverse the rotator interval.
- According to the "circle concept," anterior injuries in the shoulder must be associated with the posterior pathologies and vice versa. And interventions done anteriorly do affect the posterior structures biomechanically. The rotator interval does play a vital role in preventing posterior and inferior translation of the humeral head.
- Rotator interval closure, especially in the mediolateral direction does act as a significant biomechanical restraint in the management of the posterior instabilities of the shoulder but is not without complications. Tightening the rotator interval is associated with the significant loss of external rotation. However, the rotator interval repair especially in anterior instabilities with poor labral tissue or in revision cases where loss of external rotation may not be a problem for the patient does give biomechanical stability.

- Mediolateral closure is considered superior to the superoinferior closure considering the kinematics since the SGHL and CHL fibers travel in mediolateral directions.

F. Deltoid muscle:

- Deltoid contributes as a dynamic stabilizer by being a part of concavity compression mechanism along with the rotator cuff musculature (Fig. 3).
- This action of the deltoid is the principle on which the reverse shoulder arthroplasty functions. Complete clinicoradiological evaluation of these glenohumeral stabilizers has to be done to plan the management of the glenohumeral instability.

References

- Bost FC, Inman VT. The pathological changes in recurrent dislocation of the shoulder. *J Bone Joint Surg Am* 1942;24(3):595.
- Codman EA. *The Shoulder*. Boston: Thomas Todd; 1934.
- Steindler A. *Kinesiology of the Human Body Under Normal and Pathological Conditions*. Springfield, IL: Charles C Thomas; 1955.
- Sugaya H, Moriishi J, Dohi M, Kon Y, Tsuchiya A. Glenoid rim morphology in recurrent anterior glenohumeral instability. *J Bone Joint Surg Am* 2003;85-A(5):878-884.
- Griffith JF, Antonio GE, Tong CW, Ming CK. Anterior shoulder dislocation: Quantification of glenoid bone loss with CT. *AJR Am J Roentgenol* 2003;180(5):1423-1430.
- Gerber C, Nyffeler RW. Classification of glenohumeral joint instability. *Clin Orthop Relat Res* 2002;400:65-76.
- Itoi E, Lee SB, Berglund LJ, Berge LL, An KN. The effect of a glenoid defect on antero-inferior stability of the shoulder after Bankart repair: A cadaveric study. *J Bone Joint Surg Am* 2000;82(1):35-46.
- Lo IK, Parten PM, Burkhart SS. The inverted pear glenoid: An indicator of significant glenoid bone loss. *Arthroscopy* 2004;20(2):169-740.
- Miniaci A, Berlet G. Recurrent anterior instability following failed surgical repair: Allograft reconstruction of large humeral head defects. *J Bone Joint Surg Br* 2001;83 Suppl 1:19-20.
- Bühler M, Gerber C. Shoulder instability related to epileptic seizures. *J Shoulder Elbow Surg* 2002;11(4):339-344.
- Burkhart SS, De Beer JF. Traumatic glenohumeral bone defects and their relationship to failure of arthroscopic Bankart repairs: Significance of the inverted-pear glenoid and the humeral engaging Hill-Sachs lesion. *Arthroscopy* 2000;16(7):677-694.
- Rodosky MW, Harner CD, Fu FH. The role of the long head of the biceps muscle and superior glenoid labrum in anterior stability of the shoulder. *Am J Sports Med* 1994;22(1):121-130.
- Lippitt S, Matsen F. Mechanisms of glenohumeral joint stability. *Clin Orthop Relat Res* 1993;291:20-28.
- Halder AM, Kuhl SG, Zobitz ME, Larson D, An KN. Effects of the glenoid labrum and glenohumeral abduction on stability of the shoulder joint through concavity-compression: An in vitro study. *J Bone Joint Surg Am* 2001;83-A(7):1062-1069.
- Habermeyer P, Schuller U, Wiedemann E. The intra-articular pressure of the shoulder: An experimental study on the role of the glenoid labrum in stabilizing the joint. *Arthroscopy* 1992;8(2):166-172.
- O'Brien SJ, Neves MC, Arnoczky SP, Rozbruch SR, Dicarlo EF, Warren RF, et al. The anatomy and histology of the inferior glenohumeral ligament complex of the shoulder. *Am J Sports Med* 1990;18(5):449-456.
- Ticker JB, Flatow EL, Pawluk RJ, Soslowky LJ, Ratcliffe A, Arnoczky SP, et al. The inferior glenohumeral ligament: A correlative investigation. *J Shoulder Elbow Surg* 2006;15(6):665-674.
- Gohlke F, Essigkrug B, Schmitz F. The pattern of the collagen fiber bundles of the capsule of the glenohumeral joint. *J Shoulder Elbow Surg* 1994;3(3):111-128.
- Ticker JB, Bigliani LU, Soslowky LJ, Pawluk RJ, Flatow EL, Mow VC. Viscoelastic and geometric properties of the inferior glenohumeral ligament. *Orthop Trans* 1992;16:304-305.
- Bigliani LU, Pollock RG, Soslowky LJ, Flatow EL, Pawluk RJ, Mow VC. Tensile properties of the inferior glenohumeral ligament. *J Orthop Res* 1992;10(2):187-197.
- Savoie FH 3rd, Holt MS, Field LD, Ramsey JR. Arthroscopic management of posterior instability: Evolution of technique and results. *Arthroscopy* 2008;24(4):389-396.
- Sugalski MT, Wiater JM, Levine WN, Bigliani LU. An anatomic study of the humeral insertion of the inferior glenohumeral capsule. *J Shoulder Elbow Surg* 2005;14(1):91-95.
- Warner JJ, Lephart S, Fu FH. Role of proprioception in pathoetiology of shoulder instability. *Clin Orthop Relat Res* 1996;330:35-39.
- Lephart SM, Warner JJ, Borsa PA, Fu FH. Proprioception of the shoulder joint in healthy, unstable, and surgically repaired shoulders. *J Shoulder Elbow Surg* 1994;3(6):371-380.
- Pötzl W, Thorwesten L, Götze C, Garmann S, Steinbeck J. Proprioception of the shoulder joint after surgical repair for instability: A long-term follow-up study. *Am J Sports Med* 2004;32(2):425-430.
- Zuckerman JD, Gallagher MA, Cuomo F, Rokito A. The effect of instability and subsequent anterior shoulder repair on proprioceptive ability. *J Shoulder Elbow Surg* 2003;12(2):105-109.

Conflict of Interest: NIL
Source of Support: NIL

How to Cite this Article

Kakatkar SV, Herald J. Patho-anatomy and Patho-mechanics of Glenohumeral Instability. *Asian Journal of Arthroscopy* Jan - April 2017;1(2):3-10.