

# The McKusick-Kaufman hydrometrocolpos-polydactyly syndrome: A rare case report

Swapnil P Yewalkar, Vikas K Yadav, GJ Khadse

Department of Radiodiagnosis, B.J.M.C. and S.G.H., Pune, Maharashtra, India

**Correspondence:** Dr. Swapnil P Yewalkar, Department of Radiodiagnosis, B.J.M.C. and S.G.H., Pune - 411 001, Maharashtra, India.  
E-mail: swapnil95doc@gmail.com

## Abstract

A combination of hydrometrocolpos, polydactyly, and cardiac anomalies is the cardinal feature of McKusick-Kaufman syndrome. Neonatal hydrometrocolpos is rare Mullerian duct anomaly caused by obstruction of the vagina. There is an accumulation of mucus secretions proximal to the obstruction. The secretions are secondary to intrauterine and postnatal stimulation of uterine and cervical glands by maternal estrogens. Here, we report a case of 1-day-old neonate who presented with abdominal distension. Ultrasound and computed tomography findings revealed a large abdominopelvic cystic mass posterior to the urinary bladder. Other associated findings were polydactyly and bilateral hydronephrosis. Laparotomy confirmed the findings of hydrometrocolpos caused by stenosis/atresia of lower vagina.

**Key words:** Hydrometrocolpos; McKusick-Kaufman syndrome; polydactyly; ultrasonography; Computed tomography

## Introduction

McKusick-Kaufman syndrome (MKKS) is a rare autosomal recessive syndrome. Neonatal hydrocolpos/hydrometrocolpos, polydactyly, and congenital heart diseases are the cardinal features of MKKS.<sup>[1-3]</sup> Hydrocolpos or hydrometrocolpos caused by obstruction of the vagina accounts for 15% of abdominal masses in newborn girls. Obstruction is secondary to an imperforate hymen, or a stenotic or atretic vagina. There is an accumulation of secretions proximal to the obstruction. The secretions are secondary to intrauterine and postnatal stimulation of uterine and cervical glands by maternal estrogens.<sup>[4]</sup>

## Case Report

A new-born female neonate presented with abdominal distension. The baby had passed urine but not stools. On clinical examination, the baby had normal anal opening. Labia majora were swollen. She also had post-axial polydactyly in both hands and in a foot [Figure 1].

Erect radiograph of abdomen revealed a large soft tissue density mass involving the pelvis and most of the central part of the abdomen [Figure 2]. It was displacing the bowel loops superiorly and laterally. Bowel loops were not showing any signs of obstruction.

Ultrasound (USG) showed a large well-defined abdominopelvic cystic lesion posterior to the urinary bladder [Figure 3A and B]. It was extending up to the epigastric region superiorly and inferior to symphysis pubis inferiorly. Superiorly it was communicating with a hypoechoic tubular structure. Uterus was not seen in the pelvis. It showed uniform low-level internal echoes with fluid-debris level within it. Another large cystic, septated lesion was noted in the right adnexa. Both kidneys showed

### Access this article online

#### Quick Response Code:



Website:  
www.ijri.org

DOI:  
10.4103/0971-3026.116573

mild hydronephrosis with proximal hydroureter. This lesion was displacing the urinary bladder anteriorly and the rectum posteriorly. On USG, we suggested the diagnosis of hydrometrocolpos.

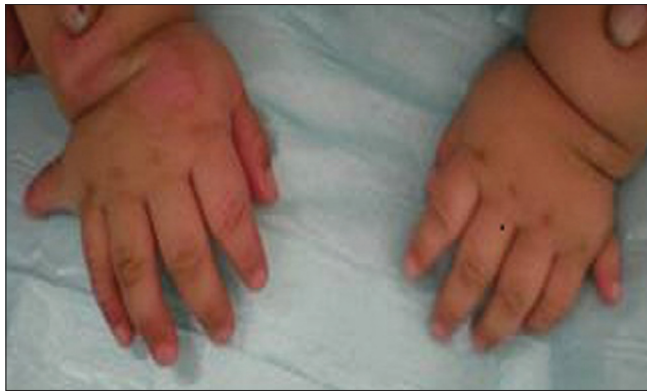A pre- and post-contrast computed tomography (CT) abdomen and pelvis revealed a large well-defined cystic lesion posterior to the bladder and anterior to the rectum [Figure 3C and D]. Superiorly it was communicating with dilated and superiorly displaced uterine cavity. Uterus appeared distended and fluid filled. Inferiorly this lesion was extending up to the vagina. Bilateral hydronephrosis and proximal hydroureter were also observed. Bowel loops appeared displaced superiorly and laterally. They were not dilated. Enhanced scan did not show any other significant abnormality.

On exploratory laparotomy, the finding of hydrometrocolpos was confirmed. The fluid that had collected was

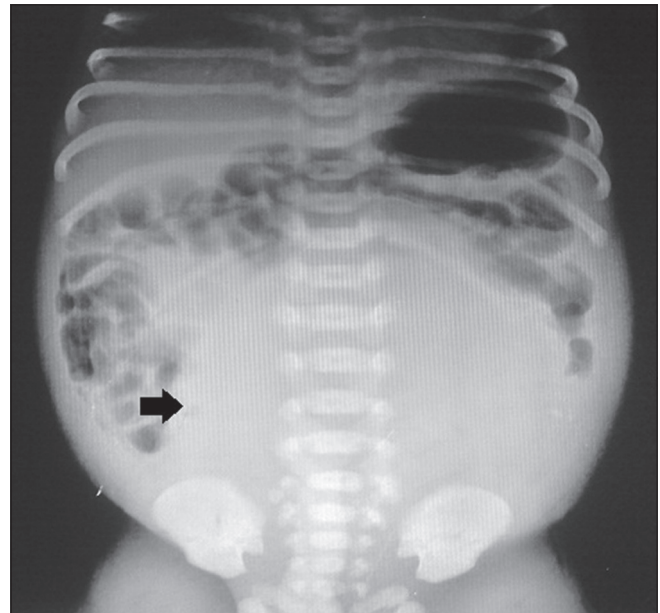
drained [Figure 4]. Atretic segment in lower third of the vagina was found for which vaginoplasty was done.

### Discussion

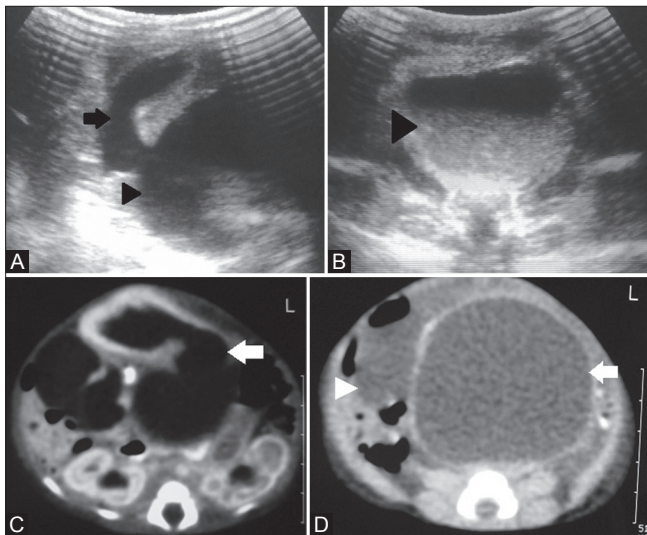
MKKS is an autosomal recessive disease. It was first described by McKusick *et al.*<sup>[1]</sup> in 1964 in two Amish sibships and rapidly confirmed.<sup>[2,3]</sup> This disease occurs due to mutation in the MKKS gene that is present at 20p12 location. Mutations in the MKKS gene result in formation of defective protein which is similar to the members of chaperonin family, leading to anomalous limbs, heart, and reproductive system.<sup>[5]</sup> Cardinal features of MKKS in females are hydrometrocolpos and polydactyly, and



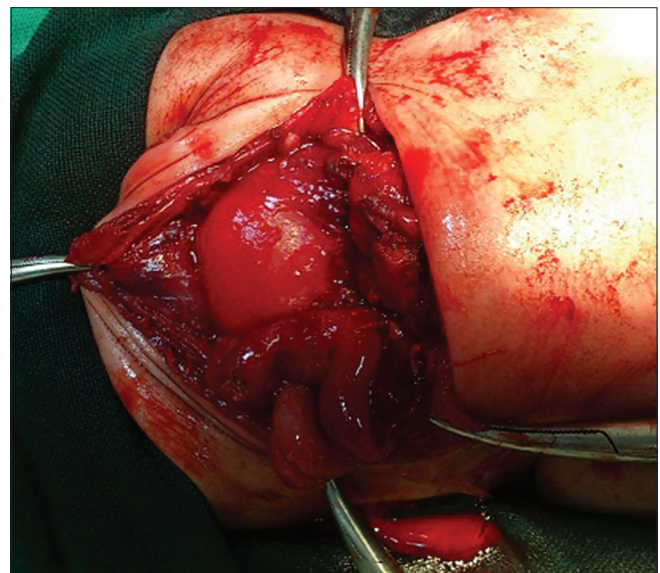
**Figure 1:** Photograph of baby's hand showing postaxial polydactyly



**Figure 2:** Erect abdomen radiograph shows large soft tissue density abdomino- pelvic mass (arrow) displacing bowel loops laterally and superiorly



**Figure 3 (A-D) :** (A, B) USG shows a large hypoechoic cystic lesion (arrow head) in pelvis with fluid-debris level communicating with distended uterine cavity (arrow) (C, D) Post-contrast axial computed tomography scan of abdomen and pelvis shows hydrometrocolpos (white arrow) with anteriorly compressed urinary bladder. Bilateral mild hydronephrosis is also noted



**Figure 4:** Intraoperative image showing hydrometrocolpos

it is often reported as the “hydrometrocolpos–polydactyly syndrome” in association with cardiac anomalies. Causes of hydrometrocolpos in most of the females are vaginal/cervical atresia or imperforate hymen. Hydrometrocolpos presents as large cystic abdominopelvic mass causing compression of the surrounding structures and secondary hydronephrosis.<sup>[4,6]</sup> Urogenital sinus is sometimes associated with hydrometrocolpos. Though MKKS is rare in males, if present, it is sometimes associated with hypospadias, chordee, and cryptorchidism. Polydactyly is present in 90% of cases. It is predominantly post-axial and rarely mesoaxial. Syndactyly may also be encountered. MKKS shows association with congenital heart defects such as atrioventricular canal defects, ventricular septal defect, and hypoplastic left heart from 10% to 20% of cases. Other less commonly associated findings are gastrointestinal abnormalities (28%) that consist of imperforate anus, rectovaginal or vesicovaginal fistula, Hirschsprung’s disease, and malrotation. Abnormalities of the eyes (5%) are also mentioned in literature.<sup>[4]</sup>

Neonatal hydrometrocolpos is an obstructive Mullerian duct anomaly. The classification of Mullerian anomalies is based on embryologic steps of lateral and vertical fusion. During lateral fusion, the Mullerian ducts develop at 5–6 weeks gestational age from the coelomic epithelium in conjunction with and lateral to the Wolffian (mesonephric) ducts. They fuse at about 7–9 weeks gestational age on the midline to form the uterovaginal canal. During vertical fusion at 8 weeks gestational age, the uterovaginal canal reaches the urogenital sinus at the Mullerian tubercle; the urogenital sinus results from separation of the cloaca into the urogenital sinus and rectum. At the same time, the vaginal plate develops distally. It proliferates first and then undergoes canalization. Therefore, the vagina is formed by both the Mullerian ducts (upper two thirds) and the urogenital sinus (lower one third).<sup>[7]</sup>

Mullerian duct anomalies are basically of two types. They can be due to Mullerian agenesis or obstruction of the Mullerian duct. Third trimester antenatal USG or USG in the neonate can diagnose MKKS by the presence of large cystic abdominopelvic mass with a fluid-debris level. Adolescents usually present with amenorrhea and cyclic abdominal pain.

USG is very valuable in differentiating between hematometocolpos due to imperforate hymen or stenotic/septate vagina from hematometra due to cervical dysgenesis. Hematometocolpos is cured by relieving the obstruction, whereas hematometra usually requires a hysterectomy.<sup>[7,8]</sup> Approximately, 45% of vaginal septa occur in the upper vagina, 40% in the middle vagina, and 15% in the lower vagina. In our case, stenosis in the lower third of vagina was found.

Bardet–Biedl syndrome (BBS) also presents with post-axial polydactyly and hydrometrocolpos. It is an autosomal recessive disorder characterized by retinal dystrophy or retinitis pigmentosa, postaxial polydactyly, obesity,

nephropathy, and mental retardation. The diagnosis can only be made if four of the five major manifestations are present in a person and remains a difficult diagnosis in infancy, as the appearance of several key features is delayed. Typically, MKKS is diagnosed in very young children, whereas the diagnosis of BBS is often delayed to the teenage years.<sup>[5]</sup> Other syndromes like Ellis–van Creveld syndrome characterized by polydactyly, acromelia, and cardiac anomalies and Pallister–Hall syndrome characterized by facial anomalies, postaxial polydactyly, imperforate anus, and CNS anomalies like diencephalic hamartoblastoma may also be considered among the differential diagnoses.<sup>[9–11]</sup>

To conclude, MKKS should be given a thought in cases of neonatal abdominal distension, especially in females. All cases of diagnosed MKKS in infancy should be reevaluated for retinitis pigmentosa and other signs of BBS, as some of these children may be affected by BBS.

## References

1. Mckusick VA, Bauer RL, Koop CE, Scott RB. Hydrometrocolpos as a simply inherited malformation. *JAMA* 1964;189:813–6.
2. Dungy CI, Aptekar RG, Cann HM. Hereditary hydrometrocolpos with polydactyly in infancy. *Pediatrics* 1971;47:138–41.
3. Kaufman RL, Hartmann HF, McAlister WH. Family studies of congenital heart disease II: A syndrome of hydrometrocolpos, postaxial polydactyly and congenital heart disease. *Birth Defects* 1972;8:85–7.
4. David A, Bitoun P, Lacombe D, Lambert JC, Nivelon A, Vigneron J, *et al.* Hydrometrocolpos and polydactyly: A common neonatal presentation of Bardet-Biedl and McKusick-Kaufman syndromes. *J Med Genet* 1999;36:599–603.
5. Stone DL, Slavotinek A, Bouffard GG, Banerjee-Basu S, Baxevasis AD, Barr M, *et al.* Mutation of a gene encoding a putative chaperonin causes McKusick-Kaufman syndrome. *Nat Genet* 2000;25:79–82.
6. Rosenberg HK, Chaudhry H. Pediatric pelvic sonography. In: Rumack CM, editor. *Diagnostic Ultrasound*. 4<sup>th</sup> ed. Philadelphia: Elsevier Mosby Publishers; 2011. p. 1936–8.
7. Rock JA. Anomalous development of the vagina. *Semin Reprod Endocrinol* 1986;4:13–31.
8. Blask AR, Sanders RC, Rock JA. Obstructed uterovaginal anomalies: Demonstration with sonography. Part II. Teenagers. *Radiology* 1991;179:84–8.
9. Ruiz-Perez VL, Ide SE, Strom TM, Lorenz B, Wilson D, Woods K, *et al.* Mutations in a new gene in Ellis-van Creveld syndrome and Weyers acrocentric dysostosis. *Nat Genet* 2000;24:283–6.
10. Al-Khenaizan S, Al-Sanna N, Teebi AS. What syndrome is this? Chondroectodermal dysplasia: The Ellis-van Creveld syndrome. *Pediatr Dermatol* 2001;18:68–70.
11. Unsinn KM, Neu N, Krejci A, Posch A, Menardi G, Gassner I. Pallister-Hall syndrome and McKusick-Kaufmann syndrome: One entity? *J Med Genet* 1995;32:125–8.

**Cite this article as:** Yewalkar SP, Yadav VK, Khadse GJ. The McKusick-Kaufman hydrometrocolpos-polydactyly syndrome: A rare case report. *Indian J Radiol Imaging* 2013;23:183–5.

**Source of Support:** Nil, **Conflict of Interest:** None declared.