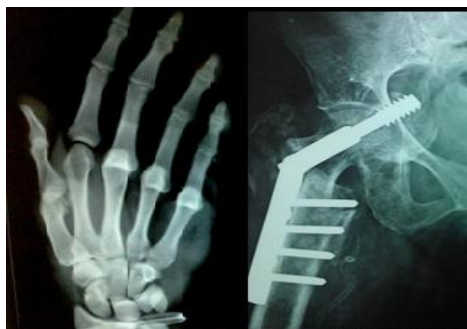



International Journal of Orthopaedics Sciences

ISSN: 2395-1958
IJOS 2019; 5(1): 128-131
© 2019 IJOS
www.orthopaper.com
Received: 06-11-2018
Accepted: 10-12-2018

Eknath Pawar
Professor and Head of unit,
Department of Orthopaedics,
Grant Medical College and JJ
Hospital, JJ Marg, Byculla,
Mumbai, Maharashtra, India

Ganesh Aher
Senior Resident, Department of
Orthopaedics, Grant Medical
College and JJ Hospital,
JJ Marg, Byculla, Mumbai,
Maharashtra, India

Abhilash Pohokar
Junior Resident -Department of
Orthopaedics, Grant Medical
College and JJ Hospital,
JJ Marg, Byculla, Mumbai,
Maharashtra, India

Nadir Zahir Shah
Associate Professor, Department
of Orthopaedics, Grant Medical
College and JJ Hospital,
JJ Marg, Byculla, Mumbai,
Maharashtra, India

Ujwal Ramteke
Assistant professor, Department
of Orthopaedics, Grant Medical
College and JJ Hospital,
JJ Marg, Byculla, Mumbai,
Maharashtra, India

Vipul Shet
Senior Resident, Department of
Orthopaedics, Grant Medical
College and JJ Hospital,
JJ Marg, Byculla, Mumbai,
Maharashtra, India

Spandan Koshire
Junior Resident, Department of
Orthopaedics, Seth Gordhandas
Sunderdas Medical College and
King Edward Memorial
Hospital, Mumbai,
Maharashtra, India

Correspondence
Ganesh Aher
Senior Resident, Department of
Orthopaedics, Grant Medical
College and JJ Hospital,
JJ Marg, Byculla, Mumbai,
Maharashtra, India

Failed intertrochanteric fracture managed with hemiarthroplasty: guide on surgical technique

**Eknath Pawar, Ganesh Aher, Abhilash Pohokar, Nadir Zahir Shah ,
Ujwal Ramteke ,Vipul Shet ,Spandan Koshire**

DOI: <https://doi.org/10.22271/ortho.2019.v5.i1c.24>

Abstract

Introduction: There have been many advances in internal fixation techniques to deal with poor quality of bone and severely comminuted intertrochanteric fractures so as to allow early ambulation. Failure rates with an internal fixation range between 3% and 12%. There have been a number of technical issues to convert these fractures into hip arthroplasty such as extraction of implants, bone deformity, bone loss, poor bone quality and associated trochanteric nonunion. Intertrochanteric fractures in osteoporotic bones which are grossly comminuted are highly unstable and difficult to treat. Rate of failure with internal fixation, with dynamic hip screws and with nail has been found to be high, especially in osteoporotic bones. Weak purchase of the internal fixation device because of osteoporosis and comminution of the fracture increases the incidence of failure of internal fixation such as cutting out the screws and displacement of the bone fragments.

Case summary: 75 years male previously operated with proximal femoral nail later had fall due to which implant failed, which were managed with implant removal with bipolar hemiarthroplasty.

Conclusion: Management of intertrochanteric fractures depends on age, stability of fracture, bone density. Young patient with good bone density should be managed with proximal femoral nail, but in older individuals with osteoporotic bone stock hemiarthroplasty is a good option. As we cannot rely on internal fixation devices to allow early full weight bearing of patients in the presence of severe osteoporosis and marked comminution at the fracture site, partial weight bearing is very difficult to be followed by these patients; thus, they shift to full weight bearing on the operated limb, causing mechanical failure. Hemiarthroplasty using bipolar prostheses for the unstable intertrochanteric fractures of the femur in elderly yields good clinical results in terms of early postoperative ambulation. This will have a direct effect on the general condition and postoperative rehabilitation.

Keywords: Intertrochanteric fracture, Bipolar hemiarthroplasty.

Introduction

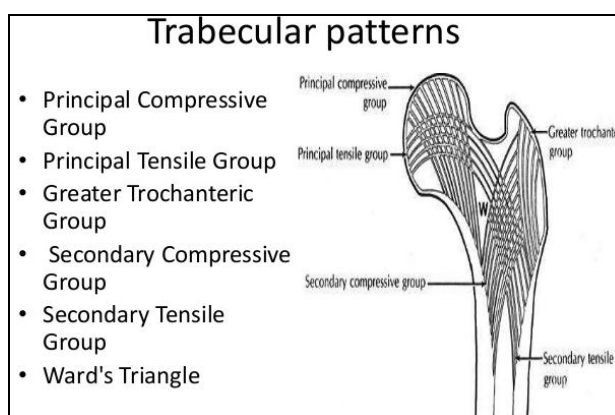


Fig: Trabecular Patterns of Proximal Femur

A trochanteric hip fracture occurs between the greater trochanter, where the gluteus medius and the gluteus minimus (hip extensors and abductors) attach, and the lesser trochanter, where the iliopsoas (hip flexor) attaches [1, 2]. The other two types of hip fractures are fractures of the femoral neck, which are proximal or cephalad to trochanteric fractures, and subtrochanteric fractures, which are distal to or below the trochanters [3, 4].

Intertrochanteric fractures in elderly population are usually treated by closed reduction and internal fixation. There have been many advances in internal fixation techniques to deal with poor quality of bone and severely comminuted intertrochanteric fractures so as to allow early ambulation [5].

Despite such advances in internal fixation of intertrochanteric fracture, there are increasing incidence of delayed union, malunion and non-union of the intertrochanteric fracture

Rate of failure with internal fixation, with dynamic hip screws has been found to be high, especially in osteoporotic bones [6].

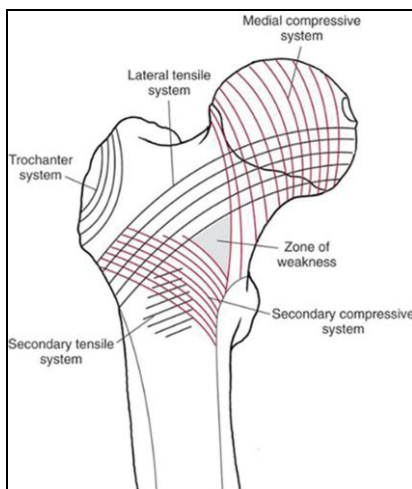


Fig 1: Compressive And Tensile System Proximal Femur

Case report

A 75 year old male patient presented with a history of trivial fall at home 6 months back complaining of right hip pain and swelling with restricted range of motion. On examination he had a swelling and tenderness at proximal thigh on lateral aspect and had a external rotation deformity of right lower limb with no distal neurovascular deficit. For which he recently got operated for right intertrochanteric # with proximal femoral nail.

Fell recently on operated limb and started having above complaints. On x ray right sided proximal femoral nail found to be dislocated Proximal screws are seen coming out and unhealed intertrochanteric # of right side seen.

Pre-op xrays:

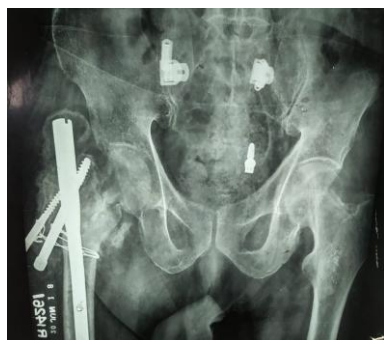

Fig 2: Pre OP Xray AP view

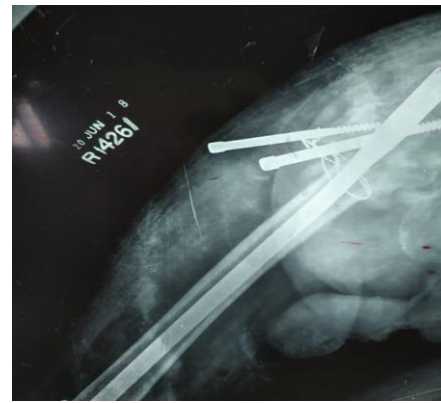


Fig 3: Pre OP Xray Oblique view

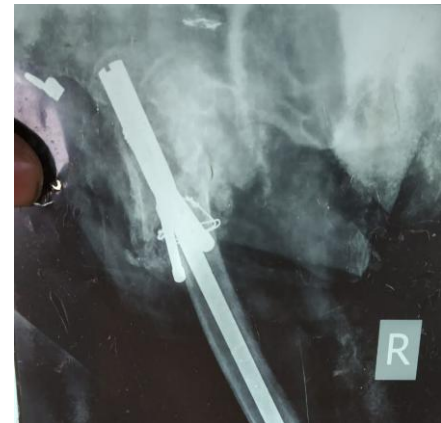

Fig 4: Pre OP Xray Lateral view

All routine investigations were done. Reports were within normal limits.

Operative procedure

In patients with proximal femoral nail, full length radiographs of the femur were obtained to know the site of entry of nail and the position of the locking screw. All instruments kept standby to remove implant such as osteotome, high speed burr, hollow mill.

We used universal extractor set for Proximal Femoral Nail removal in lateral position used posterior approach for the patient, took incision not taking account of previous incision. Source of infection rule out by Erythrocyte Sedimentation Rate, C-reactive protein, White blood cell counts and by sending swab taken from previous operated site and likely new incision site.

First we removed implant then proceed with exposure of femoral head after protecting rotators with Ethibond 5 No, dislocate the head while preserving acetabular cartilage. Canal were studded with fibrosis due to this reamer use to prepare the canal.

The femoral head and neck was removed. Meticulous care was taken to preserve the integrity of the greater trochanter, abductor muscles, and all the vascularized bone fragments. The femoral medullary canal was then reamed to the appropriate stem size and diameter.

Trial reductions were performed to determine the exact length that would provide the desired tension and tissue balancing of the abductor muscles and an equal leg length. Careful restoration of neck length, offset and version to maximize stability of the hip joint, was also performed during trial. The definitive femoral stem was cemented into the femoral canal with the use of so-called second-generation techniques (medullary lavage, use of an intramedullary cement plug,

hand-mixing of cement, use of a cement gun to deliver the cement in a doughy state in a retrograde fashion and to insert antibiotic-impregnated cement in all patients).

The lesser trochanter was not removed. Any protrusion of cement between reduced bone fragments was cleaned out. The greater trochanter was reduced and stabilized by using the tension band wiring technique after hip reduction or it was just sutured near the prosthesis. The gluteus medius muscle and vastus lateralis muscle were sutured to their anatomical locations by using anchor sutures, if necessary. Fascia lata was tightly closed over a suction drain. Greater trochanter was having hypertrophic callous which removed with burr and nibbler, used large reamers to create canal. The previous Tension band wire kept as it is, as removing it was of no use and also bone around greater trochanter were friable.

Fibrous tissues were debrided and high-speed burr was used to decorticate the bone. The trochanter was brought to the best possible anatomical position by adjusting previous Tension band wire. Image intensifier use as and when needed. Limb length was only adjusted by soft tissue tension as the local anatomy was distorted. Piriformis and posterior capsule was closed with drill holes through the greater trochanter. Drain kept in situ for 48 hrs. Check dress done on day 3 and wound found to be healthy. Several instructions given to patient regarding post-operative care. Limb kept abducted avoiding internal rotation. Patients were ambulated on the 3rd postoperative day with the help of a walker. Weight bearing according to the patient's tolerance were allowed. Patients were discharged on the 14th post-operative day after suture removal. Calcium supplementation were started.

Post op xray:

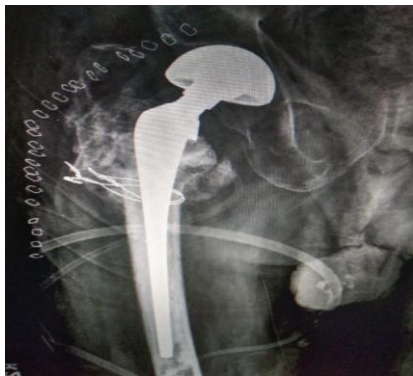

Fig 5: Post OP x ray

Follow up

Patient followed up clinically, radiologically at 2 weeks, 6 weeks, 3 months and annually thereafter. Independent observers used harris hip score, limb length measurement, visual analog score and radiological documentation. We used the harris hip score to follow the patients clinically. For cemented arthroplasty, we used radiological criteria to assess lysis according to gruen's zones.

Patient's satisfaction was assessed using the visual analog scale with the worst score being zero and the best score being ten.

Discussion

Patients with failed internal fixation of intertrochanteric fractures present with significant functional disability and pain [7]. In these elderly patients with disuse osteopenia treatment options allowing early ambulation are limited. Hip arthroplasty can provide a good salvage option for early

ambulation and restoration of normal life in this group of patients [8].

While selecting hip arthroplasty as a treatment option for these patients it must be kept in mind that this procedure is technically demanding for this particular class of patients. Poor bone quality, loss of bone stock, presence of holes after removal of hardware combined with distorted bony landmark and severe fibrosis can increase the risk of mechanical complication like fractures and cortical perforation [9]. when trochanteric non-union is present, there is usually severe fibrosis at the site leading to difficulty in exposure. These patients need exposure around the head and neck with 360° visualization of acetabular before extracting the head and neck fragment. It is mandatory to keep the capsular flaps and labrum whenever bipolar arthroplasty is being performed [10]. Patients with cephalomedullary nails in situ have neocortex formation, which makes the canal preparation challenging. In those patients without intramedullary device, the canal is blocked by fibrous tissue due to non-union, which needs careful opening. there is no proximal metaphyseal bone for stability of the implant [11]. There is a mismatch between the proximal and distal configuration; hence, most cases need distal fixation. We feel that trochanteric union may not be achieved; however, an intact soft tissue sleeve including the gluteus medius and vastus lateralis will prevent trochanteric escape and henceforth prevents instability [12].

The choice of implant-whether cemented or uncemented, total hip replacement or bipolar arthroplasty will depend upon the age of the patient, activity level, co-morbidities, quality of bone stock and acetabular damage. patients with acetabular damage due to implant penetration must deal with total hip replacement [13].

Thakur *et al.* [22] in their study of hip arthroplasty for failed intertrochanteric fractures using a modular distally fixing stem had an increase in mean harris hip score from 35.9 to 83 postoperatively. Two patients (13.3%) were walking with no aid, 10 (66.7%) were using a cane and the remaining 3 (20%) were ambulating using a walker. There were no dislocations, one patient (6.67%) had deep vein thrombosis and seven patients had heterotopic ossification (5 brooker's grade 1 and 2 grade 2). In their study, a constrained liner was used in two patients as the stability of the hip intraoperatively was questionable [14].

Haidukewych and berry [9] studied the results of hip arthroplasty in 60 patients of failed internal fixation. Of the 60, there were 32 total hip arthroplasty and 28 hemiarthroplasty. At a mean follow up of 65 months, 39 (89%) of the 44 surviving patients had no or mild pain. 91% were able to walk; 59% were ambulating with one arm support or less.

Conclusion

To conclude, hip arthroplasty for failed intertrochanteric fractures requires meticulous preoperative planning and surgical technique. Posterior hip exposure makes the procedure easy for removal of implant additionally it allow safe accessibility to the non-union of greater trochanter and intertrochanter which lies in mid of scarred tissue due to the previous surgery [15].

Inventory like universal nail extractor, nail removal *set along* with hollow mill and high speed burr are mandatory. Anatomic re-attachment of the greater trochanter is one of most important determinants of stability in these hips along with posterior capsular closure. The fact that we have had no dislocations in our study can be attributed to this technique.

Implant selection depends on age of patient, level of activity, co-morbidity, condition of the acetabulum and available proximal bone. Distal fixation was needed in those cases where there was compromised proximal bone ^[16]. Bipolar arthroplasty is an excellent option in elderly patients with co-morbidities without acetabular damage. Pt were allowed to bear weight post-operatively as tolerated and all were ambulatory at final follow up. Thus, hip arthroplasty is a good alternative option for these failed intertrochanteric fractures ^[17].

References

1. Kuntscher G. A new method of treatment of peritrochanteric fractures. Proc r soc med. 1970; 63:1120.
2. Grosse A, Kempf I, Lafforgue D. Fen chir Orthop. 1978; 64:33.
3. Russel TA. Fractures of hip and pelvis: in crenshaw ah (ed): campbell's operative orthopaedics (8th ed). St louis: cv mosby, 1992, 895.
4. Evans EM. The treatment of trochanteric fracture of femur. J bone joint surg (br). 1949; 31:190-203.
5. Gotfried Y. The lateral trochanteric wall. Clin orthop. 2004; 425:82-86.
6. Kyle RF, Gustilo RB, Premer RF. Analysis of 622 intertrochanteric hip fractures-a retrospective and prospective study. J bone joint surg (am). 1979; 61:216-21.
7. Boyd HB, griffin ll. Classification and treatment of trochanteric fractures. Arch surg. 1949; 38:853.
8. Goldhaggen PR, O'connor DR, Schumarze D. *et al.* Prospective comparative study of compression hip screw in the gamma nail. J orthop trauma. 1994; 8:367-72.
9. Leung KS, SO WS, Shung WY *et al.* Gamma nails and dynamic hip screws for peritrochanteric fractures-a randomized prospective in the elder patients. J bone joint surg (am). 1992; 74:345-51.
10. Radford PJ, Needoff M, Webb JK. A prospective prolonged comparison of the dynamic hip screw and the gamma locking nail. J bone joint surg (br).1993; 75b:789-93.
11. Williams WW, Parker BC. Complications associated with use of the gamma nail. Injury. 1992; 23:291.
12. Medoff RJ, Maes K, Mitsunaga M, Chappuis Jl. Axial compression screw: anew implant for the fixation of the high subtrochanteric and unstable intertrochanteric fractures of the hip. Poster exhibit at the 53rd annual meeting of the american academy of orthopaedic surgeons, new orleans, 1990.
13. Cheug C, Chow SP, Leons TCV. Long term results and complications of cement augmentation in the treatment of unstable trochanteric fractures. Injury, 1989, 134.
- Karani R, Meier De. Systemic pharmacologic postoperative pain management in the geriatric orthopaedic patient; clin orthop. 2004, 425.
14. Baumgaertner MR, Curtin SL, Lindskog DM, Keggi JM. The value of the tip-apex distance in predicting failure of fixation of peritrochanteric hip fractures of the hip, j bone joint surg (am). 1995; 77:1058. [pubmed]
15. Spivak JM, Zuckerman JD, Kummer FJ *et al.* Fatigue failure of sliding screw in hip fracture fixation-report of three cases. J orthop trauma. 1991; 3:325-31.
16. Tordis TC. Stress analysis of femur. J biomech. 1969; 2:163.