



## ENDOSCOPIC THERAPY OF TRAUMATIC BILE LEAKS

## Gastroenterology

<b>Dr Malladi Uma Devi</b>	MD, DM Gastroenterology, Associate Professor Of Gastroenterology, Gandhi Medical College, Secunderabad.
<b>Dr Abdul Samad Peshimam*</b>	DM Post Graduate, Department Of Gastroenterology, Gandhi Medical College , Secunderabad. *Corresponding Author
<b>Dr Abhinay Raja Rao P</b>	DM Post Graduate, Department Of Gastroenterology, Gandhi Medical College, Secunderabad.
<b>Dr Swapnika Gadde</b>	DM Post Graduate, Department Of Gastroenterology, Gandhi Medical College, Secunderabad.
<b>Dr Shravan Kumar P</b>	MD DM, Gastroenterology, Professor And Hod Of Gastroenterology, Gandhi Medical College, Secunderabad.

## ABSTRACT

Traumatic bile leaks often result in high morbidity and prolonged hospital stay that requires multimodality management. Data on endoscopic management of traumatic bile leaks are scarce. Our study objective was to evaluate the efficacy of the endoscopic management of a traumatic bile leak. We performed a retrospective case review of patients who were referred for endoscopic retrograde cholangiopancreatography (ERCP) after traumatic bile duct injury secondary to blunt trauma (motor vehicle accident or fall from height) for management of bile leaks at our tertiary hospital. Thirty patients underwent ERCP for the management of a traumatic bile leak over a 10 year period. The etiology included blunt trauma from motor vehicle accident in 20 patients or fall from height accident in 10 patients. Liver injuries were grade III in 10 patient, grade IV in 20 patients. All patients were treated by biliary stent placement, and the outcome was successful in 30 of 30 cases (100%). The mean duration of follow-up was 90 days. There were no ERCP-related complications. In our case review, endoscopic management with endobiliary stent placement was found to be successful and resulted in resolution of the bile leak in all 30 patients. Based on our study results, ERCP should be considered as first-line therapy in the management of traumatic bile leaks.

## KEYWORDS

## INTRODUCTION:

The main cause of noniatrogenic injury to the biliary system is trauma. Bile leaks can result from penetrating injury, such as gunshot (GSW) or knife wounds, or from blunt trauma, such as motor vehicle accidents or fall from height. The incidence of bile leaks following hepatobiliary trauma ranges from 0.5 to 21% depending on the criteria and methods used to diagnose the bile leak [1–3]. Following blunt or penetrating abdominal trauma, there can be significant damage to the biliary tract with severe injuries (grades III–VI) leading to an intrahepatic biloma, intraperitoneal leakage of bile, hemobilia and bilhemia, and intra-abdominal abscess [1]. There is no consensus on the treatment of traumatic bile leaks and decisions are often based on extent and mechanisms of injury, associated organ injuries and local expertise.

Regardless of the etiology, bile leaks can be a considerable cause of morbidity in afflicted patients. Unstable patients, as well as those with a penetrating injury, require laparotomy in conjunction with less invasive techniques. Hemodynamically stable patients with blunt hepatic trauma can be managed nonoperatively which has become the treatment of choice over the past two decades [4]. In earlier years, the main treatment options were surgical. However, the treatment of bile leaks has evolved with improvements in technology and procedural techniques.

The management of surgical bile leaks with therapeutic endoscopic retrograde cholan-giopancreatography (ERCP) is well-established [5, 6]. However, the diagnosis of traumatic bile leaks can often be delayed and difficult. It has been suggested that posttraumatic bile leaks require more therapeutic procedures, patients have longer hospital courses, and higher hospital charges [7]. ERCP has been found to be a useful tool for the diagnosis and treatment of posttraumatic bile leaks, but data on outcome after therapeutic ERCP for traumatic bile leaks is limited [1, 3, 8, 9]. Several case reports and a case series in the surgical literature report that ERCP can be useful in the management of traumatic bile leaks [8]. A variety of endoscopic techniques have been used to manage bile leaks. These include biliary sphincterotomy alone, biliary stenting with or without sphincterotomy, and nasobiliary drainage with or without sphincterotomy. These methods share the

common goal of de-creasing or eliminating the pressure gradient between the bile duct and duodenum, allowing preferential flow of bile from the duct into the duodenum instead of bile exiting the leak site. The absence of ongoing bile flow through the leak site allows the defect to heal [1, 8].

We conducted a retrospective case review to evaluate the role of ERCP in the management of patients who present with a bile leak after blunt abdominal trauma.

## Patients and Methods

The prospectively recorded endoscopy data was reviewed to identify all patients who underwent ERCP for the management of traumatic bile leaks between March 2010 and March 2020. All patients who developed a posttraumatic bile leak were included, regardless of the mechanism of injury or the initial method of management (operative vs. nonoperative).

All patients were admitted to the trauma service and were initially managed in the surgical intensive care unit. 30 out of 30 patients underwent surgical exploration with percutaneous drain placement. A bile leak was suspected when there was persistent drainage of bile through an intra-abdominal drain placed at surgery, after percutaneous drainage of a perihepatic fluid collection, or when a computed tomography (CT) scan revealed a subhepatic fluid collection and bile leak was confirmed with the help of MRCP.

Patients underwent ERCP in the endoscopy unit with the assistance of anesthesia, using a combination of midazolam and Ketamine. Once a bile leak was demonstrated on cholangiogram, a biliary sphincterotomy was performed routinely in all patients then a 7.0 Fr or 8.0 Fr transpapillary biliary stent was placed. After the ERCP, surgically or percutaneously placed drains were removed after there was decreased or absent output from the drains. The patients were monitored daily after ERCP for 48 hr to assess for any complications and again in clinic 1–2 weeks after discharge.

Endoscopic therapy was considered successful if there was absent bile

output from the drains. Failure of endoscopic therapy was defined as persistence of biliary drainage through the percutaneous drain or persistence of biloma on CT that necessitated additional interventions to manage the bile leak. All bile leaks had resolved and the previously placed endobiliary stent was removed after a period of 3 months.

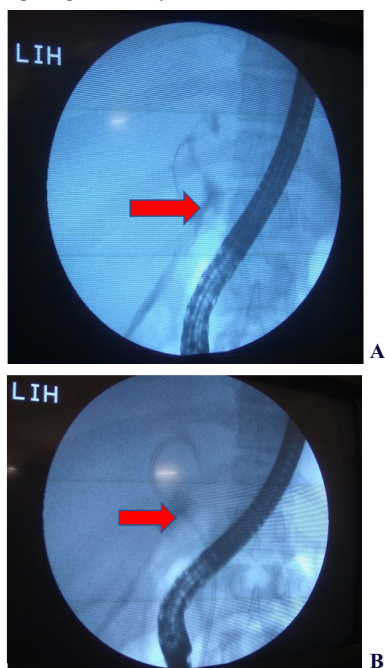
To assess the long-term outcome, follow-up data were obtained by telephone contact with the patients, who were questioned specifically about any evaluation or treatment of a recurrent bile leak, as well as complications, subsequent to their last endoscopic treatment. All patients or their immediate relatives provided informed consent for the procedure.

## RESULTS

A total of 30 patients (all were age range 10–50 years), between March 2010 to March 2020, underwent ERCP for a bile leak secondary to traumatic injury to the abdomen. All 30 cases were because of blunt trauma: MVA in 20 and 10 due to fall from height. Injuries were graded according to predefined criteria [10] and were grade III (<3 cm parenchymal laceration) in 10 patient, grade IV (25–75% parenchymal disruption) in 20 patients. ERCP was successful in all patients. A biliary sphincterotomy was performed in all patients. Bile leaks were located in the right ductal system in 10 patients and in the left ductal system in 20. All the 30 patients underwent surgery for other associated injuries. Other associated injuries included lacerations to the spleen, diaphragm, kidney or major abdominal vessels, and hemothorax. Details on patient demographics and the nature of bile duct injury with location, interventions, and outcomes are shown in table 1. There were no documented post-ERCP complications.

All patients had an endobiliary stent placed. All the 30 patients were initially managed with surgery with subsequent ERCP with endobiliary stent placement. Follow-up ERCP done in all patients which revealed resolution of the bile leak and the stent was removed after a period of 3 months.

Of note, 10 of the 30 patients had delayed presentation of the bile leak. 10 of the 30 patients developed bilious output from the surgically placed drain on postoperative day 8.



**Figure A** arrow indicates the leak in the left ductal system. **Figure B** arrow indicates stent placed in the left ductal system bridging the leak.

## DISCUSSION

This study showed that ERCP with sphincterotomy and endobiliary stent placement is effective in the treatment of patients with major bile duct damage after hepatobiliary trauma. In our series, the resolution of a bile leak was seen in 100% of patients who underwent endobiliary stent placement and sphincterotomy. This data is supported by a recent

study reported by Lubezky et al. [8], where ERCP with biliary sphincterotomy and stent placement was found to be effective in all 11 patients who developed a traumatic bile leak. Also, in a study by Bridges et al. [9], resolution of a traumatic bile leak was seen in 90% of patients who underwent endobiliary stent placement.

Biliary ductal injuries may not be seen on initial imaging or laparotomy and can therefore have an insidious presentation. The biliary injuries that result from hepatic trauma may be simple bile leaks into the lacerated liver, peritoneal cavity or pleural cavity or may result in biliary-vascular fistulas. Bile leaks usually present several days after the initial trauma, with the patient complaining of abdominal pain, increasing abdominal distention, and ascites. presentation of bile leak can be delayed up to two weeks as was reported previously [11].

The biliary injury can be intrahepatic, extrahepatic or both. In our series all the 30 patients had injuries to the intrahepatic ductal system. 10 of the 30 cases had involvement of the right intrahepatic ductal system. The other 20 cases involved the left intrahepatic ductal system. In previous series, the right intrahepatic ducts were the predominant sites of bile leaks following abdominal trauma [1, 9, 12]. Whether or not the location of the bile leak can predict treatment outcome is still unclear and cannot be elicited from our study or others.

Hepatobiliary injuries can be complex and management remains a challenge to surgeons. Surgery has been the conventional treatment for posttraumatic bile leaks but can be difficult to perform due to a combination of adhesions, inflammation, damaged liver parenchyma or the patient being a poor surgical risk. The most important factors that influence survival in these patients are the associated injuries and the nature and the extent of liver injury [13]. It has been shown that liver-related complications appear to be less frequent in patients managed without surgery than in those managed surgically [8–10]. Nonoperative management of bile duct injury is effective with success rate ranging from 90 to 94%. In our series, the resolution of bile leak was seen in all patients following endoscopic treatment. The success rate of therapeutic endoscopic intervention ranges from 90 to 100% [1, 8, 9, 12]. Sugiyama et al. [3] reported healing of bile leaks in 5 of 6 patients after therapeutic ERCP. In a series by Bajaj et al. [14], therapeutic ERCP was successful in 8 of 9 (89%) patients for managing posttraumatic bile leaks. Bridges et al. [9] reported healing of bile leaks in 9 of 10 (90%) patients after biliary stenting. Hence, an ERCP is both of diagnostic and therapeutic benefit in these patients.

In the present series, resolution of bile leak was documented on repeat ERCP which was done 12 weeks after initial ERCP. Sharma et al. [12] documented resolution of bile leak after 8.5 days (range 3–30 days) of endoscopic interventions. In a series by Singh et al. [1], bile leaks closed in 15.76 days in patients who had undergone sphincterotomy, and in 12.14 days in patients without sphincterotomy. Lubezky et al. [8] reported resolution of bile leaks in 6–7 days (range 5–10 days) after ERCP. Sugiyama et al. [3] reported healing of bile leaks after 1–7 days of ERCP. Bajaj et al. [14] reported time to resolution of bile leak after ERCP as 7.4 days (range 2–17 days).

We routinely perform biliary sphincterotomy and endobiliary stent placement for the management of a bile leak. There were no complications related to endoscopic sphincterotomy. There are, however, several studies that clearly demonstrate the efficacy of biliary stent placement alone in this cohort of patients [3]. Other series support our combined approach of endoscopic sphincterotomy and stenting for management of bile leaks following hepatic trauma [8, 9, 12]. In major leaks it is unlikely that sphincterotomy alone can seal the leak [15].

The ideal length of time for stenting is not known. It has varied from 3 to 8 weeks in previously published reports [1]. We removed the stents after an interval of 12 weeks.

Follow-up in our patients ranged from 90 to 150 days. None of our patients showed evidence of post-ERCP complications. In a study by Sugiyama et al. [3] on long-term follow-up, there were no late complications after endoscopic treatment. In the series by Sharma et al. [12], after a mean follow-up of 33 months, there were no complications and all the patients remained asymptomatic.

The limitations of this study include the retrospective case series design as well as the small number of subjects included in the series. This particular cohort is small in the general population, and thus these

procedures are rarely undertaken. The follow-up was also short and thus some long-term complications from ERCP could have occurred.

In summary, this study demonstrated the efficacy of ERCP with sphincterotomy and endobiliary stent placement in the management of patients with extensive traumatic hepatic injury with intrahepatic bile leaks. The severity of an injury and the site of a bile leak do not preclude endotherapy as a management option in these patients. The results of our series and those of previously published series suggest that ERCP should be considered as a first-line therapy for traumatic bile leaks.

**TABLE 1:**

No	Age/sex	Etiology	Location of bile leak	Grade of injury	Biliary stent (Fr)	Other biliary interventions	Follow up days	outcome
1	33/M	MVA	RDS	3	7	Surgery	92	success
2	42/M	MVA	LDS	4	7	Surgery	96	success
3	25/M	FHA	LDS	3	7	Surgery	102	success
4	35/M	MVA	RDS	3	8	Surgery	112	success
5	37/M	MVA	LDS	4	7	Conservative	97	success
6	13/M	FHA	RDS	4	8	Surgery	99	success
7	43/M	FHA	LDS	3	8	Surgery	113	success
8	29/F	MVA	LDS	4	7	Surgery	95	success
9	45/M	MVA	LDS	3	8	Surgery	143	success
10	26/M	MVA	RDS	3	8	Conservative	123	success
11	33/M	FHA	RDS	4	7	Surgery	112	success
12	41/M	MVA	LDS	4	7	Conservative	135	success
13	34/F	MVA	LDS	3	8	Surgery	145	success
14	53/M	FHA	RDS	4	7	Conservative	125	success
15	27/M	MVA	LDS	3	8	Surgery	127	success
16	25/M	MVA	LDS	4	7	Surgery	137	success
17	27/F	MVA	RDS	4	7	Conservative	150	success
18	33/M	FHA	LDS	3	8	Surgery	142	success
19	32/M	FHA	LDS	4	8	Surgery	134	success
20	37/F	MVA	RDS	4	7	Conservative	127	success
21	23/M	MVA	LDS	3	8	Surgery	126	success
22	36/M	MVA	RDS	4	7	Conservative	136	success
23	38/M	FHA	LDS	4	7	Conservative	147	success
24	40/M	MVA	LDS	4	7	Surgery	139	success
25	22/M	FHA	LDS	4	8	Surgery	140	success
26	26/F	MVA	LDS	4	8	Surgery	91	success
27	29/M	MVA	RDS	4	8	Surgery	98	success
28	30/M	FHA	LDS	4	8	Conservative	94	success
29	37/M	MVA	LDS	4	8	Surgery	95	success
30	32/M	MVA	LDS	4	8	Conservative	92	success

**MVA:**MOTOR VEHICLE ACCIDENT. **FHA:**FALL FROM HEIGHT ACCIDENT

**RDS:**RIGHT DUCTAL SYSTEM. **LDS:**LEFT DUCTAL SYSTEM.

## REFERENCES

- Singh V, Narasimhan KL, Verma GR, Singh G: Endoscopic management of traumatic hepatobiliary injuries. *J Gastroenterol Hepatol* 2007;22:1205-1209.
- Pachter HL, Knudson MM, Esrig B, Ross S, Hoyt D, Cogbill T, Sherman H, Scalea T, Harrison P, Shackford S, Ochsner MG, Mucha P, Hofstetter SR, Guth A, Coffey S, Kataju S, Marburger R, Garcia J, Savage B, Henry S, Lippold, D, Trevesani G, Steinig J: Status of nonoperative management of blunt hepatic injuries in 1995: a multicenter experience with 404 patients. *J Trauma* 1996;40:31-38.
- Sugiyama M, Atomi Y, Matsuoka T, Yamaguchi Y: Endoscopic biliary stenting for treatment of persistent biliary fistula after blunt hepatic injury. *Gastrointest Endosc* 2000;51:42-44.
- Cogbill TH, Moore EE, Jurkovich GJ, Feliciano DV, Morris JA, Mucha P: Severe hepatic trauma: a multicenter experience with 1,335 liver injuries. *J Trauma* 1988;28:1422-1438.
- Johnston TD, Gates R, Reddy KS, Nickl NJ, Ranjan D: Nonoperative management of bile leaks following liver transplantation. *Clin Transplant* 2000;14:365-369.
- Kaffes AJ, Hourigan L, De Luca N, Byth K, Williams SJ, Bourke MJ: Impact of endoscopic intervention in 100 patients with suspected postcholecystectomy bile leak. *Gastrointest Endosc* 2005;61:269-275.
- Vassiliu P, Toutouzas KG, Velmahos GC: A prospective study of posttraumatic biliary and pancreatic fistuli. The role of expectant management. *Injury* 2004;35:223-227.
- Lubezky N, Konikoff FM, Rosin D, Carmon E, Kluger Y, Ben-Haim M: Endoscopic sphincterotomy and temporary internal stenting for bile leaks following complex hepatic trauma. *Br J Surg* 2006;93:78-81.
- Bridges A, Wilcox CM, Varadarajulu S: Endoscopic management of traumatic bile leaks. *Gastrointest Endosc* 2007;65:1081-1085.
- Moore EE, Cogbill TH, Jurkovich MD, Shackford SR, Malangoni MA, Champion HR: Organ injury scaling: spleen and liver (1994 revision). *J Trauma* 1995;38:323.
- Spinn MP, Adler DG: Successful endoscopic therapy of intrahepatic bile leaks following hepatic gunshot injury: report of two cases. *Endoscopy* 2006;38:859.
- Sharma BC, Mishra BC, Kumar R, Sarin SK: Endoscopic management of bile leaks after blunt abdominal trauma. *J Gastroenterol Hepatol* 2009;24:757-761.
- Fabian TC, Croce MA, Stanford GG, Payne LW, Mangiante EC, Voeller GR, Kudsk KA:

Factors affecting morbidity following hepatic trauma. A prospective analysis of 482 injuries. *Ann Surg* 1991;213:540-548.

- Bajaj JS, Spinelli KS, Dua KS: Postoperative management of noniatrogenic traumatic bile duct injuries: role of endoscopic retrograde cholangiopancreatography. *Surg Endosc* 2006;20:974-977.
- Costamagna G: Benign biliary strictures and leaks; in Ginsberg G, Kochman ML, Norton I, et al (eds): *Clinical Gastrointestinal Endoscopy*, ed 1. London, Elsevier, pp 695-708.