Review Article

Left bundle branch pacing: Case-based discussion of concept and criteria

ABSTRACT

Cardiac pacing is the mainstay of therapy for symptomatic bradyarrhythmias due to conduction system disease. However, traditional right ventricular apical or septal pacing results in dyssynchronous activation of the left ventricle and pacing-related cardiomyopathy in a subset of patients. Conduction system pacing, by directly capturing elements of the cardiac conduction system aims to produce physiologic activation of the ventricles. His bundle pacing, while being the most physiologic way of achieving this, suffers from certain limitations. Left bundle branch (LBB) pacing has emerged in recent times as a promising alternative modality of conduction system pacing. In this review, we outline the concept and criteria for successful LBB pacing through illustrative cases.

Keywords: Conduction system pacing, criteria, left bundle branch pacing, physiological pacing

INTRODUCTION

Cardiac pacing is the only effective therapy for symptomatic bradycardia in the absence of reversible causes. Right ventricular (RV) apical pacing has been in widespread use for >50 years but causes electrical and mechanical dyssynchrony in the ventricles, with an attendant increased long-term risk for heart failure and atrial fibrillation.[1,2] Pacing at alternative RV sites, such as the septum or outflow tract, has not been shown to be superior to RV apical pacing.[3,4]

This has led to renewed interest in physiological pacing by recruiting the conduction system. His bundle pacing (HBP), by screwing an active fixation lead at the His bundle location to capture the His [Figure 1a] was first successfully achieved by Deshmukh *et al*., and published more than two decades back.[6] Despite being the most physiological modality of ventricular pacing, HBP has some limitations. HBP has a narrow target range and identifying the precise location can be challenging. Owing to the location of the His bundle at the Tricuspid annulus, low R-wave amplitude, and large atrial signals can be encountered, resulting in ventricular undersensing and atrial oversensing. A late rise in the pacing threshold has been described in 5%–10% of patients. Damage to the His bundle during implantation and risk of lead dislodgement are other potential concerns. Finally, although even bundle branch blocks are often intra-Hisian and corrected in many instances by HBP owing to longitudinal dissociation of fibers within the His, true infra-Hisian conduction system block cannot be overcome by HBP.[7-11]

Left bundle branch pacing (LBBP) can potentially solve many of the limitations associated with HBP. LBBP was first described by Huang *et al*., in which the pacing lead is penetrated deep into the inter-ventricular septum (IVS) to place it subendocardially in the left ventricle (LV) at the location of the left bundle branch (LBB). By directly capturing the LBB fibers, it achieves synchronous LV activation and

Ritesh Acharya, Kumar Narayanan

Department of Cardiac Electrophysiology, Medicover Hospitals, Hyderabad, Telangana, India

Address for correspondence: Dr. Kumar Narayanan, Department of Cardiac Electrophysiology, Medicover Hospitals, Hitec City, Madhapur, Hyderabad - 500 084, Telangana, India. E-mail: kumardoc96@yahoo.com

Submitted: 12-Dec-2023 **Revised:** 22-Jan-2024
Accepted: 22-Jan-2024 **Published:** 14-Feb-2024

Access this article online	
Website: https://journals.lww.com/mjm	Quick Response Code
DOI: 10.4103/MJM.MJM_6_23	

How to cite this article: Acharya R, Narayanan K. Left bundle branch pacing: Case-based discussion of concept and criteria. Medicover J Med 2024;1:1-6.

physiological pacing [Figure 1b]. As the lead location is completely ventricular, deep in the IVS, LBBP is characterized by a stable lead position, lower risk of dislodgement, a low and stable pacing threshold, ability to overcome truly infra Hisian block and a relative technical ease of implantation due to a wider target, as the broad LBB occupies a wider area compared to the narrow His bundle. Hence in recent times, LBBP has increasingly become the more preferred mode of conduction system pacing.[12]

In this paper, we illustrate the concept of LBBP and elucidate the criteria for satisfactory LBB capture through a case-based approach.

Case 1

A 63-year-old female, a known case of systemic hypertension, type 2 diabetes mellitus (DM) and hypothyroidism presented with exertional fatigue and shortness of breath. She had bradycardia at presentation with a pulse rate of 40/min. A 12 lead electrocardiogram (ECG) showed 2:1 atrioventricular (AV) block, right bundle branch block (RBBB), ventricular rate of 44/min [Figure 2a]. Her baseline blood parameters were normal. A coronary angiogram showed normal epicardial coronaries. Dual chamber permanent pacemaker implantation with LBB pacing was planned in view of the symptomatic 2:1 AV block. Echocardiogram showed normal LV systolic function with basal IVS thickness (1.5 cm distal to atrioventricular (AV) leaflet attachment) of 12 mm. Knowing IVS thickness at the site of LBB lead placement is important to ascertain the depth of safe penetration and avoid perforation into the LV cavity. The distance from the tip of the helix to the anode is 10.8 mm in the Medtronic SelectSecure 3830 lead.

Procedure steps

A temporary pacing lead was placed in RV apex and a quadripolar electrophysiology catheter was placed at His location via the right femoral vein route to serve as a landmark to guide left bundle lead placement. A standard left infraclavicular subcutaneous pacemaker pocket was created and two left axillary venous accesses were taken. A Medtronic Select-Secure lumenless 3830 69 cm long lead was introduced via a Medtronic C315 His preshaped long sheath (Medtronic Inc., CA, USA). Alligator clips were attached to the lead and skin to display intracardiac signals and pace from the lead tip in unipolar mode. The preshaped sheath has a primary and secondary (septal) curve, which helps to reach the point of interest in the IVS. The sheath was advanced into the RV in the right anterior oblique 30° view and then further along an imaginary line connecting the His catheter to the RV apex to a spot about 1.5–2 cm distal to the His location [Figure 3a and b]. Contact was achieved on the IVS with the distal tip of the lead extended just beyond the sheath. Pacing through the lead tip was done and its position was fine-tuned to obtain a paced QRS morphology showing a notched QRS (W pattern) in V1, R wave in lead II, rS wave in lead III, and discordant QRS in aVR (negative) and aVL (positive). Obtaining this QRS morphology indicates that the lead is in the right position to capture the LBB after penetrating the IVS. The initial impedance reading before lead penetration was noted. Changing to left anterior oblique 30° view, the sheath was rotated counterclockwise to orient it perpendicular to the IVS and provide good support

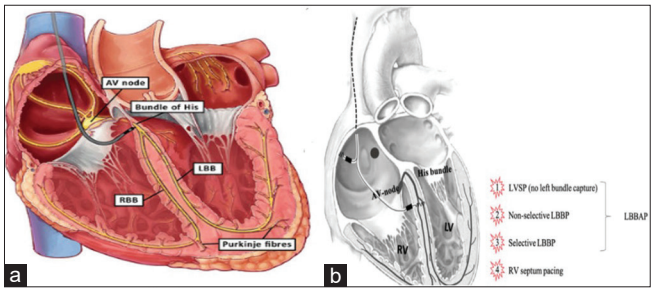

Figure 1: (a) Illustration of His bundle pacing, (b) Schematic overview of heart and conduction system illustrating where the lead penetrates interventricular septum to achieve left bundle branch pacing. AV: Atrioventricular, LVSP: Left ventricular septal pacing, LBB: Left bundle branch, LBBP: LBB pacing, RBB: Right bundle branch, LBBAP: left bundle branch area pacing, LV: Left ventricle, RV: Right ventricle (Reproduced from Heckman *et al*.[5])

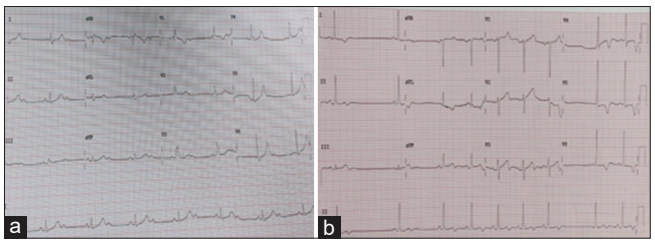

Figure 2: (a) Electrocardiogram (ECG) showing 2:1 atrioventricular block with right bundle branch block in Case 1, (b) ECG showing sinus node dysfunction in Case 2

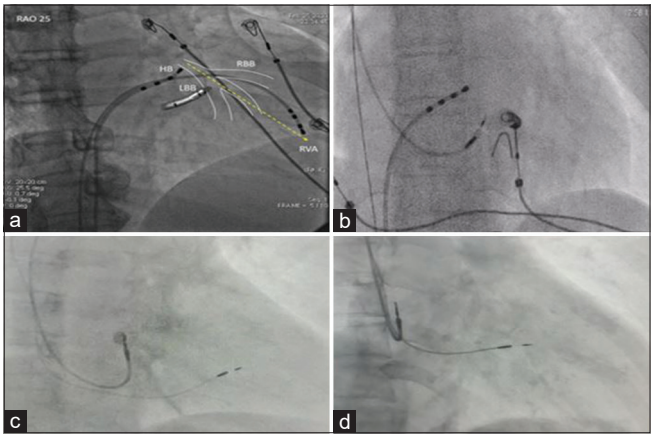

Figure 3: (a and b) Fluoroscopic views in the right anterior oblique showing the site of the left bundle branch pacing lead implantation (Reproduced from Ponnusamy *et al*.[13]) (c and d) Final fluoroscopic images of Case 1 and Case 2, respectively. RAO: Right anterior oblique, HB: His Bundle, RBB: Right bundle branch, LBB: Left bundle branch, RVA: Right ventricular apex

for lead penetration. Five to six rapid turns were then given to the lead to penetrate the IVS. Ventricular ectopics, if any, generated during lead penetration (fixation beats) were documented. An initial increase in impedance followed by a drop and a good current of injury were used as indicators of adequate lead penetration. Sufficient R wave amplitude, low pacing threshold and LBB capture were checked and gradual additional turns were given as needed to achieve LBB capture with good parameters. The impedance and current of injury in the ventricular electrogram are carefully monitored while penetrating the IVS with the lead. An excessive fall in impedance (to <500 Ω) or loss of injury current indicates perforation into the LV cavity. In that case, the lead has to be completely removed and re-positioned in a fresh location. Once the lead had adequately penetrated and LBB capture confirmed, the sheath was slit and parameters rechecked. The final unipolar pacing impedance was >500 Ω.

This was followed by the fixation of the atrial lead in RA appendage, confirming lead parameters and fixing both leads to the pulse generator.

Intra-procedure criteria for left bundle capture

Criteria used to determine LBB capture are listed in Table 1 and Figure 4. These include both ECG-based and intracardiac electrogram-based criteria. First, lead V1 should show a qR, Qr, or rsR' pattern. As the left bundle is being captured, it follows that V1 would show a RBBB-like morphology. The R wave peak time measured from the pacing spike to the peak of the R wave in lateral precordial leads (V5 and V6; also called peak LV activation time) should be short (<80 ms) and fixed at both high and low pacing outputs, showing that the lead is placed exactly at the LBB, leading to early activation of LV lateral wall. The presence of an LBB potential recorded from the pacing lead tip can be considered the gold standard for ideal lead location; this is a sharp potential 15–30 ms before QRS. Demonstration of transition from nonselective to selective left bundle capture (with isoelectric interval between pacing spike and QRS) as the pacing output is reduced also serves to confirm that the lead is placed exactly at the LBB location. Ideally, all the above criteria should be demonstrated to confirm LBB capture specifically rather than mere LV septal myocardial capture, close to the LBB. These criteria are checked in unipolar pacing mode to have a pure representation of information from the pacing lead tip only. However, it is noteworthy that in finally pacing through the permanent pacemaker, bipolar, AV synchronous pacing is typically employed. This often gives rise to a narrow QRS without a classical RBBB pattern due to some myocardial capture from the anode on the RV septal side as well as varying degrees of fusion with intrinsic right bundle activation depending on the AV delay. Hence, the postprocedure ECGs may not reveal the same QRS pattern as obtained during intra-procedural testing [Figure 5a and b].

The final sensed R wave at implantation was 10.2 mV and the threshold was 1.1 V. The postprocedure fluoroscopic image is shown in Figure 3c. Postprocedure ECG showed atrial sensing with ventricular pacing with a narrow QRS duration of 80 ms

Table 1: Parameters assessed to ascertain left bundle branch capture [Figures 4 and 7]

	Case 1	Case 2
qR, Qr or rsR' pattern in lead V1	+	+
Narrow and fixed paced V6 RWPT (ms)	At 5 V: 61 At 1.5 V: 62	At 5 V: 77 At 1.5 V: 79
Left bundle potential	+	+
Nonselective to selective LBB capture transition from higher output to lower output	+	+
V6-V1 interpeak interval (ms)	37	33

LBB: Left bundle branch, V6RWPT: V6-R wave peak time

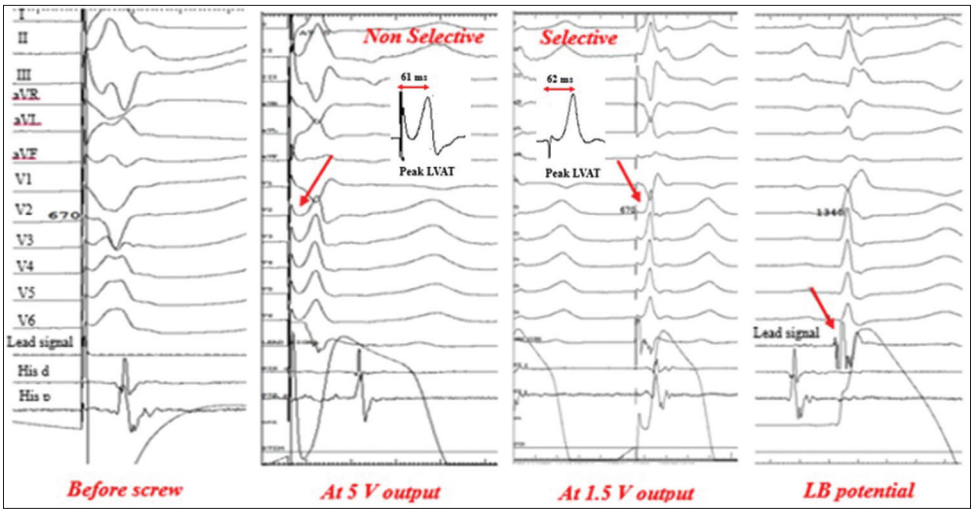

Figure 4: Electrograms during the left bundle branch capture in Case 1. LVAT: Left ventricular activation time; LB: Left bundle

due to recruitment of the left bundle [Figure 5a]. Lead positions in postprocedure chest X-ray are depicted in Figure 6a.

Case 2

A 76-year-old female, a known case of type II DM, systemic hypertension and coronary artery disease post revascularisation to the left anterior descending coronary artery in 2019 presented with exertional fatigue. ECG showed intermittent sinus bradycardia, atrial ectopics, and sinus pauses up to 1.8 seconds [Figure 2b]. Holter study showed sinus bradycardia with the lowest daytime heart rate of 39 bpm; brief atrial runs and pauses of up to 2.2 s suggestive of sick sinus syndrome. The echocardiogram was normal with a basal IVS thickness of 11.5 mm (1.5 cm distal to AV leaflet attachment).

Procedure steps

Similar procedural steps were followed as for Case 1 and successful LBB capture was obtained [Figure 7 and Table 1]. The final R wave amplitude at implantation was 18.0 mV and the threshold was 1.5 V. The postprocedure ECG showed atrial pacing with ventricular sensing. Postprocedure fluoroscopic image, ECG, and chest X-ray are depicted in Figures 3d, 5b, and 6b, respectively.

DISCUSSION

LBB pacing is increasingly being used as the preferred mode of conduction system pacing in view of its advantages over HBP. The learning curve for LBB pacing is also likely to be lesser compared to HBP. Various criteria have been put forward to ensure LBB capture during lead implantation.[14] The paced QRS morphology, during unipolar LBBP, shows the pattern of RBBB in V1 lead or improving the LBB conduction in patients with LBB block (LBBB).[15,16] The RBBB pattern is usually incomplete and is influenced by the level of capture of the distal His bundle or proximal left bundle, distal conduction system disease, and septal-Purkinje connections.

With capture of the LBB during LBBP, we may demonstrate the LBB potential about 15–30 ms earlier to QRS.[17,18]

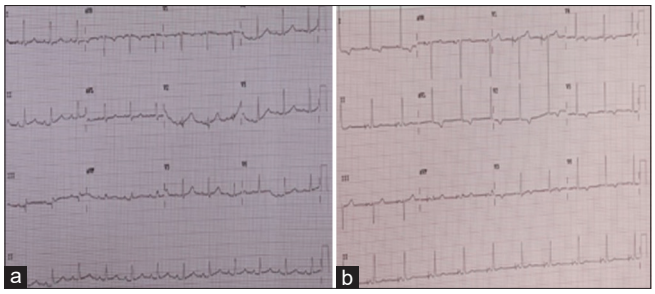

Figure 5: (a) Post left bundle branch (LBB) pacing electrocardiogram (ECG) showing A sensing, V pacing, PR interval 200 ms, QRS rate 72/min, and QRS duration 80 ms (Case 1), (b) Post-LBB pacing ECG showing A pacing, V sensing, PR interval 180 ms, QRS rate 60/min (Case 2)

The interval from the LBB potential to V6-R wave peak time (V6RWPT) in intrinsic rhythm should be equal to the interval from stimulus to V6RWPT during pacing. Allowing for variability in measurement, a difference <10 ms has a sensitivity of 88.2% and specificity of 95.4% for confirming LBB capture.[19]

The paced R wave peak time (RWPT) is measured from the onset of the pacing spike to the peak of the R wave in leads V5 and V6.[12] It is an indicator of the rapidity of LV-free wall activation, useful to identify the depth of the pacing lead and capture of the LBB. On LBB capture, paced RWPT remains short and fixed at both high and low outputs. In patients with narrow QRS or isolated RBBB, V6RWPT <74 ms was 100% specific (albeit only 40% sensitive) for LBB capture, while a cutoff of ≤80 ms was 100% specific in patients with LBBB, nonspecific intraventricular conduction delay, and wide QRS escape rhythm.[19] For practical purposes, cutoffs of <75 and <80 ms may be used, respectively.[20]

During implantation, the pacing amplitude is slowly decreased to demonstrate a transition between simultaneous capture of both LBB and septal myocardium (nonselective-LBBP) to selective capture of either only LBB (s-LBBP) or only LV septal myocardium. Only 26.4% of patients with LBB/fascicular capture showed this feature in the MELOS registry,[21] but the demonstration of s-LBBP has been reported in up to 75.4% of patients at implantation (and 30.9% at follow-up) when targeting more proximal LBBP sites.[22]

The novel V6–V1 interpeak interval criterion uses a patient-specific reference (V1 R-wave peak, reflecting RV activation) to assess LV activation and is less impacted by conduction system disease than V6RWPT. The optimal cutoff is >33 ms,[23] with a sensitivity of 71.8% and specificity of 90.0% for LBB capture, whereas >44 ms was 100% specific.[24]

All the above-mentioned criteria were duly satisfied by the two cases discussed here.

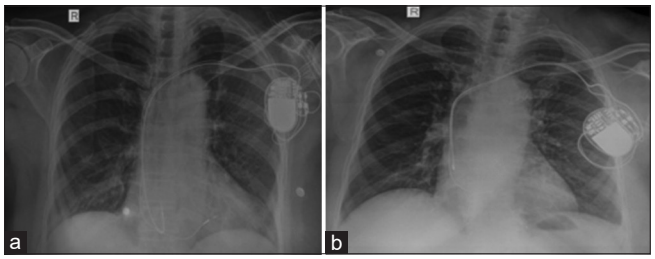

Figure 6: (a) Post left bundle branch (LBB) pacing Chest X-ray (Case 1), (b) Post LBB pacing Chest X-ray (Case 2)

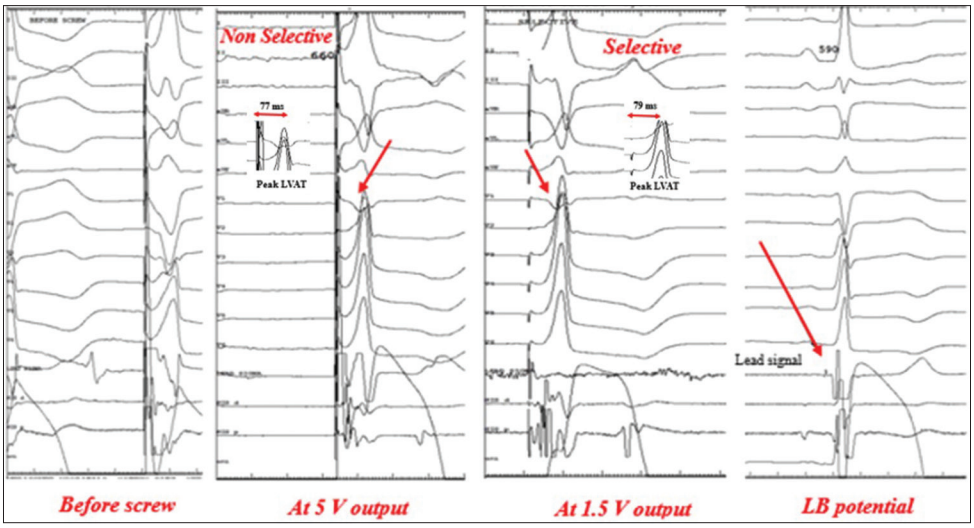

Figure 7: Electrograms during left bundle branch capture in Case 2. LVAT: Left ventricular activation time; LB: Left bundle

In view of the ability to efficiently capture the LBB, giving rise to narrow QRS and early LV free wall activation, LBB pacing is being actively investigated as an alternative to cardiac resynchronization therapy (CRT) with promising results.[25,26] Remaining knowledge gaps with regard to LBBP include a lack of long-term data, concerns about lead fracture at the hinge point where the lead penetrates the IVS as well as future lead extraction if needed, as the lead is buried deep in the IVS. Ongoing studies and registries with LBBP will give greater clarity on these issues.

CONCLUSION

LBB pacing is a rapidly evolving mode of conduction system pacing. With increase in experience, the criteria for LBB capture are getting further refined. It preserves all the advantages of conduction system recruitment, obtaining physiologic pacing, while overcoming some of the limitations of traditional HBP. A stepwise approach and meticulous assessment of proposed LBB capture criteria during implantation are needed to ensure success. With its role in bradycardia pacing as well as resynchronization therapy in heart failure patients, LBB pacing has the ability to transform the pacing landscape in the near future.

Declaration of patient consent

The authors certify that they have obtained all appropriate patient consent forms. In the form, the patient(s) has/have given his/her/their consent for his/her/their images and other clinical information to be reported in the journal. The patients understand that their names and initials will not be published and due efforts will be made to conceal their identity, but anonymity cannot be guaranteed.

Financial support and sponsorship

Nil.

Conflicts of interest

There are no conflicts of interest.

REFERENCES

1. Nielsen JC, Kristensen L, Andersen HR, Mortensen PT, Pedersen OL, Pedersen AK. A randomized comparison of atrial and dual-chamber pacing in 177 consecutive patients with sick sinus syndrome: Echocardiographic and clinical outcome. J Am Coll Cardiol 2003;42:614-23.
2. Sweeney MO, Hellkamp AS, Ellenbogen KA, Greenspon AJ, Freedman RA, Lee KL, *et al.* Adverse effect of ventricular pacing on heart failure and atrial fibrillation among patients with normal baseline QRS duration in a clinical trial of pacemaker therapy for sinus node dysfunction. Circulation 2003;107:2932-7.
3. Zografos TA, Siontis KC, Jastrzebski M, Kutyifa V, Klein HU, Zareba W, *et al.* Apical versus non-apical right ventricular pacing in cardiac resynchronization therapy: A meta-analysis. Europace 2015;17:1259-66.
4. Shimony A, Eisenberg MJ, Filion KB, Amit G. Beneficial effects of right ventricular non-apical versus apical pacing: A systematic review and meta-analysis of randomized-controlled trials. Europace 2012;14:81-91.
5. Heckman LI, Luermans JG, Curila K, Van Stipdonk AM, Westra S, Smisek R, *et al.* Comparing ventricular synchrony in left bundle branch and left ventricular septal pacing in pacemaker patients. J Clin Med 2021;10:822.
6. Deshmukh P, Casavant DA, Romanyshyn M, Anderson K. Permanent, direct his-bundle pacing: A novel approach to cardiac pacing in patients with normal his-Purkinje activation. Circulation 2000;101:869-77.
7. Vijayaraman P, Chung MK, Dandamudi G, Upadhyay GA, Krishnan K, Crossley G, *et al.* His bundle pacing. J Am Coll Cardiol 2018;72:927-47.
8. Lustgarten DL, Crespo EM, Arkhipova-Jenkins I, Lobel R, Winget J, Koehler J, *et al.* His-bundle pacing versus biventricular pacing in cardiac resynchronization therapy patients: A crossover design comparison. Heart Rhythm 2015;12:1548-57.
9. Subzposh FA, Vijayaraman P. Long-term results of his bundle pacing. Card Electrophysiol Clin 2018;10:537-42.
10. Barba-Pichardo R, Moriña-Vázquez P, Fernández-Gómez JM, Venegas-Gamero J, Herrera-Carranza M. Permanent his-bundle pacing:

Seeking physiological ventricular pacing. Europace 2010;12:527-33.
11. Zanon F, Ellenbogen KA, Dandamudi G, Sharma PS, Huang W, Lustgarten DL, *et al.* Permanent his-bundle pacing: A systematic literature review and meta-analysis. Europace 2018;20:1819-26.
12. Huang W, Su L, Wu S, Xu L, Xiao F, Zhou X, *et al*. A novel pacing strategy with low and stable output: Pacing the left bundle branch immediately beyond the conduction block. Can J Cardiol 2017;33:1736.e1-e3.
13. Ponnusamy SS, Arora V, Namboodiri N, Kumar V, Kapoor A, Vijayaraman P. Left bundle branch pacing: A comprehensive review. J Cardiovasc Electrophysiol 2020;31:2462-73.
14. Burri H, Jastrzebski M, Cano Ó, Čurila K, de Pooter J, Huang W, *et al.* EHRA clinical consensus statement on conduction system pacing implantation: Endorsed by the Asia Pacific Heart Rhythm Society (APHRS), Canadian Heart Rhythm Society (CHRS), and Latin American Heart Rhythm Society (LAHRS). Europace 2023;25:1208-36.
15. Chen K, Li Y. How to implant left bundle branch pacing lead in routine clinical practice. J Cardiovasc Electrophysiol 2019;30:2569-77.
16. Vijayaraman P, Subzposh FA, Naperkowski A, Panikkath R, John K, Mascarenhas V, *et al.* Prospective evaluation of feasibility and electrophysiologic and echocardiographic characteristics of left bundle branch area pacing. Heart Rhythm 2019;16:1774-82.
17. Zhang S, Zhou X, Gold MR. Left bundle branch pacing: JACC review topic of the week. J Am Coll Cardiol 2019;74:3039-49.
18. Li X, Li H, Ma W, Ning X, Liang E, Pang K, *et al.* Permanent left bundle branch area pacing for atrioventricular block: Feasibility, safety, and acute effect. Heart Rhythm 2019;16:1766-73.
19. Jastrzębski M, Kiełbasa G, Curila K, Moskal P, Bednarek A, Rajzer M, *et al.* Physiology-based electrocardiographic criteria for left bundle branch capture. Heart Rhythm 2021;18:935-43.
20. Wu S, Chen X, Wang S, Xu L, Xiao F, Huang Z, *et al.* Evaluation of the criteria to distinguish left bundle branch pacing from left ventricular septal pacing. JACC Clin Electrophysiol 2021;7:1166-77.
21. Jastrzębski M, Kiełbasa G, Cano O, Curila K, Heckman L, De Pooter J, *et al.* Left bundle branch area pacing outcomes: The multicentre European MELOS study. Eur Heart J 2022;43:4161-73.
22. Su L, Wang S, Wu S, Xu L, Huang Z, Chen X, *et al.* Long-term safety and feasibility of left bundle branch pacing in a large single-center study. Circ Arrhythm Electrophysiol 2021;14:e009261.
23. Briongos-Figuero S, Estévez-Paniagua Á, Sánchez-Hernández A, Muñoz-Aguilera R. Combination of current and new electrocardiographic-based criteria: A novel score for the discrimination of left bundle branch capture. Europace 2023;25:1051-9.
24. Jastrzębski M, Burri H, Kiełbasa G, Curila K, Moskal P, Bednarek A, *et al.* The V6-V1 interpeak interval: A novel criterion for the diagnosis of left bundle branch capture. Europace 2022;24:40-7.
25. Liang Y, Wang J, Gong X, Lu H, Yu Z, Zhang L, *et al.* Left bundle branch pacing versus biventricular pacing for acute cardiac resynchronization in patients with heart failure. Circ Arrhythm Electrophysiol 2022;15:e011181.
26. Jastrzębski M, Moskal P, Huybrechts W, Curila K, Sreekumar P, Rademakers LM, *et al.* Left bundle branch-optimized cardiac resynchronization therapy (LOT-CRT): Results from an international LBBAP collaborative study group. Heart Rhythm 2022;19:13-21.