



# A Short Review of Thrombolysis in Ischemic Stroke Patients on Anticoagulants

**Satya Rao<sup>1\*</sup>; Chitranjan Naidu<sup>2</sup>; Likhitha<sup>3</sup>**

<sup>1</sup>Former professor of Neurology, senior consultant, Medicover Hospitals, Visakhapatnam.

<sup>2</sup>Consultant Emergency Physician, Medicover Hospitals, Visakhapatnam.

<sup>3</sup>Junior Resident, Neurology, Medicover Hospitals, Visakhapatnam.

## \*Corresponding Author(s): K Satya Rao

Former professor of Neurology, senior consultant,  
Medicover Hospitals, Visakhapatnam.

Email: drsatyarao@rediffmail.com

## Abstract

Thrombolysis is the treatment of choice in acute ischemic stroke patients." TIME IS BRAIN "It's fulfilled when they reach in window period. However in the patients who are on anticoagulants can we go ahead with thrombolysis or not IS the dilemma which is still existing. The earlier guidelines indicate absolute contraindication in patients who are on anticoagulants {ECASS 3 exclusion criteria}[1]. Recent guidelines indicate that with INR 1.7 we can thrombolyse. We present here "A CASE OF DOUBLE VALVE REPLACEMENT ON WARFERIN THERAPY IS THROMBOLYSED IN ACUTE ISCHEMIC STROKE "a decision which we have taken and gave a normal life in 5 days.

Received: Nov 29, 2022

Accepted: Dec 21 2022

Published Online: Dec 23, 2022

Journal: Annals of Neurology and Neurosurgery

Publisher: MedDocs Publishers LLC

Online edition: <http://meddocsonline.org/>

Copyright: © Satya Rao K (2022). This Article is distributed under the terms of Creative Commons Attribution 4.0 International License

## Introduction

Thrombolysis is the treatment of choice in patients with acute ischemic stroke if the patient reaches hospital in the Window period which is extended from 3.00 hrs to to 4.5 hours in the recent guidelines. However if the patient is on anticoagulant therapy for other problems like cardiovascular or other thrombo embolic manifestations whether to thrombolyse or not is the problem where we have to take decision depending on some of the guidelines laid down by AHA and ASA. It is said that the patients who are on vit k anticoagulants like Warferin can be thrombolysed if the INR is below 1.7. Those who have INR More than 1.7 need 4F PCC and Vit k 10mg Iv can be given and thrombolysed. Those who are on Non vit k anticoagulants are to be given the corresponding antidote and be thrombolysed [2].

The antidote for Dabigatran is Idarucizumab and the antidote for factor xa inhibitors is Andexanet alfa these are to be given prior to thrombolysis in those patients who were on Non vit k anticoagulants and correct the coagulation profile [3]. The bleeding tendency of intra cerebral hemorrhage is more with Non vit k anticoagulants than with Warferin. Various studies showed that the thrombolysis was successful when given in the window period for acute ischemic strokes after correcting the INR. It's a tough job to correct the INR and thrombolyse with in the available shortest period. There are many studies which showed successful thrombolysis in aortic valve replacement surgery, in patients with AF and embolic stroke and other thromboembolic strokes less number of studies are seen in double valve replacement surgery with stroke while on anticoagulants who underwent successful thrombolysis.



Here we present a case of Post DVR who developed acute ischemic stroke while on Warferin 4mg per day and successful recovery with thrombolysis.

Case vignette: A 53 year old male patient a known diabetic on treatment presented with acute onset of left sided weakness. He underwent DVR 1 year back and is on Warferin 4mg per day. He attended the emergency department 1hour after the weakness.

Clinical examination showed-drowsy, following verbal commands He had gaze paresis to left. Left upper motor facial palsy and left hemiplegia with grade 2 /5 power. His plantar reflex was extensor.

He was evaluated in Emergency department. His MRI brain showed acute infarct in the Right MCA territory. Because he was on Warferin we were worried regarding thrombolysis and his PT with INR was tested. The INR was found to be 1.1.His blood sugar, LFT and RFT were with in normal range. His 2 DECHO showed normal valves, normal function and no clot. He was started on Tenecteplase 0.25 mg per kg body weight and monitored hourly. There was no deterioration any further and Patient showed gradual improvement. On day 2 he was walking with support and on day 5 he walked out without any support. On day 10 he walked out of the hospital on his own. He regained normal power and went home .Here we have given TENACTEPLASE which is having long half-life than Alteplase and is economical. Direct single bolus dose can be given. The comparative studies with Tenecteplase V/S Alteplase showed that the tenecteplase is better choice [4]. We had good result with Tenecteplase with a timely decision to thrombolysate in a Patient who is on Warferin. The last dose of Warferin was 12 hrs before coming to emergency department.

Take home message: The patients with ischemic stroke who are on anticoagulants can be thrombolysed if they reach the Emergency department with in the window period and have INR less than 1.7.Those who have INR more than 1.7 need antidote and can be thrombolysed to have good out come and normal life.

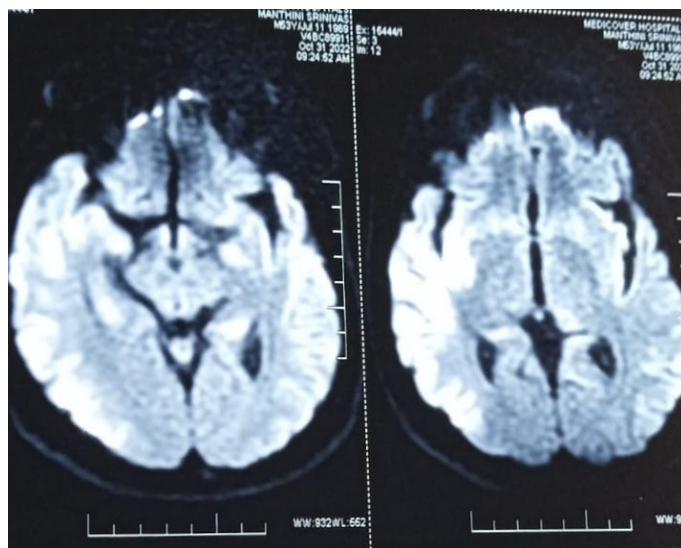


Figure 1: MRI Brain before Thrombolysis.

### References

1. Topçuoğlu MA, Murat Arsava E, Özcan Özdemir A, Gürkaş E, Necioğlu Örken D, et al. Intravenous Thrombolytic Therapy in Acute Stroke: Problems and Solutions. *Turk J Neurol.* 2018; 24: 13-25.
2. Chausson N, Soumah D, Aghasaryan M, Altarcha T, Alecu C, et al. Reversal of Vitamin K Antagonist Therapy Before Thrombolysis for Acute Ischemic Stroke. *Stroke.* 2018 ; 49: 2526-2528.
3. Kermer P, Schellinger PD, Ringleb PA, Köhrmann M. SOP: thrombolysis in ischemic stroke under oral anticoagulation therapy. *Neurol Res Pract.* 2022; 4: 7.
4. Requião LE, Oliveira RS, Reis LS, Assis APB, Moreno BNG, et al. Short-Term Efficacy Outcomes of Tenecteplase versus Alteplase for Acute Ischemic Stroke: A Meta-Analysis of 5 Randomized Trials. *Neurol India.* 2022; 70: 1454-1459.