

Original Research Article

A three year prospective study-suspected acute appendicitis: diagnostic accuracy of modified Alvarado score versus ultrasonography in adults

Murhari D. Gaikwad^{1*}, Anand Auti¹, Avinash Magare²

¹Department of Surgery, IIMS and R Medical College, Warudi, Jalna, Maharashtra, India

²Department of PSM, IIMS and R Medical College, Warudi, Jalna, Maharashtra, India

Received: 29 October 2017

Accepted: 13 November 2017

*Correspondence:

Dr. Murhari D. Gaikwad,

E-mail: drmurharigaikwad@gmail.com

Copyright: © the author(s), publisher and licensee Medip Academy. This is an open-access article distributed under the terms of the Creative Commons Attribution Non-Commercial License, which permits unrestricted non-commercial use, distribution, and reproduction in any medium, provided the original work is properly cited.

ABSTRACT

Background: To evaluate and compare diagnostic accuracy of modified Alvarado score and ultrasonography in correlation to histopathology report for diagnosis of acute appendicitis.

Methods: A prospective study of the patients who underwent appendectomy for suspected acute appendicitis at IIMS and R Medical College and Noor Hospital Warudi, Badnapur, Dist. Jalna (Maharashtra). The clinical (radiological) and ultrasonography data of 760 patients with suspected appendicitis was collected between March 2014 to Feb. 2017. These patients were evaluated by modified Alvarado score and ultrasonographically, which was corrected with histopathological finding.

Results: Out of 760 patients 69.34% had acute appendicitis 63.81% had modified Alvarado score ≥ 7 and 58.28% patients were ultrasonographically positive. In present study modified Alvarado score has sensitivity of 89.37% specificity 93.99% positive predictive value 97.11%, negative predictive value 79.64%, diagnostic accuracy of 81.32%.

Conclusions: Modified Alvarado score can be used effectively in clinical decision making. When compare with ultrasonography neither one is advantageous. However, additional information provided by ultrasonography improves diagnostic accuracy.

Keywords: Alvarado score, Appendectomy, Ultrasonography

INTRODUCTION

Globally, acute appendicitis is a common surgical emergency with life time risk of 1 (after 7) which means that 6% of the individuals suffer an attack during their life time.¹⁻³ The condition is difficult to diagnose during the early stages when the classical signs and symptoms are usually subtle.^{1,4} Different disease process mimic the diagnosis of acute appendicitis as there are number of causes leading to pain in the right iliac fossa particularly in female patients.^{5,6} It has been observed that many patients undergoing appendectomy prove to be negative

on histopathology of the surgically removed appendix, which is the gold standard for diagnosis of appendicitis.² Removing a normal appendix is a burden both on patients and health resources.¹

However, early recognition of the condition and prompt operation have been the most important factors in reducing morbidity and possible mortality length of stay and the cost of treatment. It has been claimed that diagnostic aids can dramatically reduce the number of negative appendectomies.⁵ These aids include laparoscopy, scoring systems, ultrasonography,

computerized axial tomography scans and magnetic resonance imaging and have different advantages and disadvantages. Graded compression ultrasonography in diagnosis of acute appendicitis has greatly improved the ability to diagnose acute appendicitis.¹ Ultrasonography is operator dependant and the care to be taken to avoid over interpreting a technically inadequate examination. The accuracy offered by sonography should keep negative laparotomy ratio at approximately 10%, which is improvement over the rate achieved by instinct alone.²

CT scan is complimentary to sonography. However, CT scan is associated with greater cost, exposure to ionizing radiation and exposure to contrast agents. The modified Alvarado score is a 9-point scoring system for the diagnosis of appendicitis based on clinical signs and symptoms and a leucocytes count score of 7 or more were recommended for surgery.⁷

In our (IIMS and R and Noor) Hospital acute appendicitis remain one of the most common acute abdominal emergencies warranting surgery in patients presenting with atypical clinical findings so diagnosis become difficult. Modified Alvarado scoring system and ultrasonography play a definite role in diagnosis of acute appendicitis, because of its easy availability, cost effectiveness and radiation free.

METHODS

The present study is conducted in the Department of Surgery IIMS and R Medical College and Noor Hospital during the period of March 2014 to February 2017. Study design was a prospective study. Patients with suspected clinically acute appendicitis and undergone

appendectomy in Indian Institute of Medical Science and Research and Noor Hospital Warudi, Badnapur, Jalna were selected for the study.

760 adults having acute appendicitis who underwent modified Alvarado score evaluation and ultrasonography at IIMS and R Medical College and Noor Hospital Warudi, Jalna were selected for the study.

Inclusion criteria

All the patients undergoing appendectomies in Noor Hospital Warudi, Jalna, Adults (Male and Female) age group 15 to 60 years.

Exclusion criteria

Other pathologies like benign and malignant tumours of appendix, appendicular mass managed conservatively, worm infection.

The patients who were admitted and operated depending on clinical suspicion of acute appendicitis, the clinical diagnosis of acute appendicitis was done by consultants of Department of IIMS&R Medical College and Noor Hospital Warudi, Jalna based on clinical signs and symptoms.

The patients suspected of acute appendicitis undergo through evaluation by clinical details, investigations and ultrasonography. Then depending on the clinical details and investigations, they were allotted modified Alvarado score which is as follows. In modified Alvarado scoring system where shift to left is removed.

Table 1: The Alvarado scores for diagnosis of acute appendicitis.

		Alvarado score
Symptoms	Migratory right iliac fossa pain	1
	Nausea/vomiting	1
	Anorexia	1
Signs	Right iliac fossa tenderness (RIF)	2
	Elevation of temperature	1
	Rebound tenderness (RIF)	1
Laboratory	Leukocytosis	2
Findings	Neutrophilic shift to the left (75%)	1
Total score		10

Patients with a score of ≥ 7 points have a high risk of appendicitis. Patients with a score of < 5 points have a very low risk of appendicitis. Modified Alvarado score more than or equal to 7 are considered acute appendicitis i.e. positive and score less than or equal to 6 are considered negative. The ultrasonography findings are noted depending upon the findings they were divided in

two groups. One is ultrasonography positive and ultrasonography negative.

The appendix specimen is sent for histopathology report and the report is noted. Histopathology diagnosis is considered final. The modified Alvarado score and ultrasonography findings are compared to histology

report with the help of 2x2 tables, the sensitivity, specificity, positive predictive value, negative predictive value and diagnostic accuracy were calculated individually and then compared with each other.

RESULTS

Total number of cases in this study were 760 out of 760 patients, 406 (53.42%) were male and 354 (46.57%) were female. Out of all the patients undergone appendectomy 527 (68.02%) was histologically positive for acute appendicitis and 233 (30.65%) were histologically

negative. All the 760 patients were assigned modified Alvarado score among which 63.81% (485) were positive (≥ 7) and 36.18% (275) were negative (≥ 6) by the patients undergone for ultrasonography had 443 (58.28%) positive and 317 (41.71) were sonographically negative. In the present study, modified Alvarado score has sensitivity of 89.37% specificity 93.99% positive predictive value 97.11%, negative predictive value 79.64% diagnostic accuracy 90.79%. Ultrasonography had sensitivity of 78.56%, specificity of 87.55%, and positive predictive value of 64.35%, negative predictive value of 64.35%, diagnostic value of 81.32%.

Table 2: Comparison of modified Alvarado score and ultrasonography in diagnosis of acute appendicitis.

	Modified Alvarado	Ultrasonography	Modified Alvarado score and ultrasonography
Sensitivity	89.37%	78.56%	97.34%
Specificity	93.99%	87.55%	97%
Positive predictive value	97.11%	93.45%	98.65%
Negative predictive value	79.64%	64.35%	94.17%
Diagnostic accuracy	90.79%	81.32%	97.24%

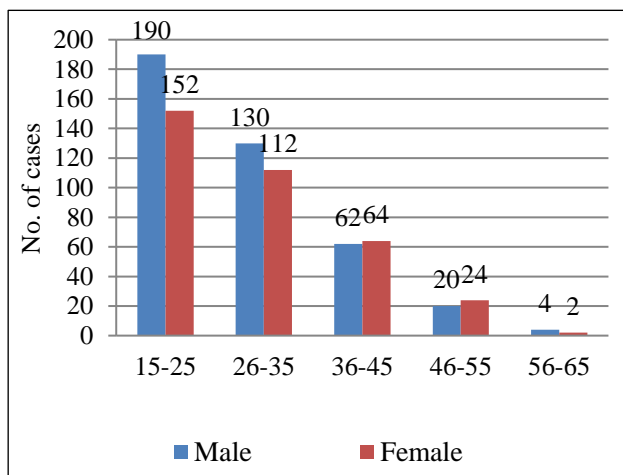


Figure 1: Gender wise incidence of acute appendicitis with relation to age.

DISCUSSION

In 1986, Alvarado followed up patients admitted to surgical unit at the Nazareth Hospital in Philadelphia with suspected acute appendicitis, until surgery confirmed or refuted diagnosis. He found out eight criteria had high diagnostic accuracy for acute appendicitis. Alvarado scoring system was modified by Kalen et al and named it as modified Alvarado scoring system. Later on, many studies were conducted with modified Alvarado scoring system, few of them were in favour and other was against it. But the author also suggested the need for a prospective study to evaluate modified Alvarado score.

Ultrasonography is rapid, non-invasive, inexpensive and requires no patient preparation or contrast material administration.^{7,8}

Although operator skill is an important factor in all ultrasonography patients with right lower quadrant pain. The appendix appears on ultrasound as a lamellated, elongated blind-ending structure. Unlike normal bowel, the inflamed appendix is fixed, non-compressible and appears round on transverse images. Measurements of appendix are performed with full compression.

Traditionally, the diagnosis of appendicitis is made when the diameter of the compressed appendix exceeds 6 mm. In contrast, the thick walled and non-compressible appendix, maintained in a fixed position by the compressing transducer will show circumferential colour when inflamed. Appendiceal perforation can be diagnosed when the appendix demonstrates irregular contour or when peri appendiceal fluid collection are identified.^{1,2,7}

Doppler ultrasound examination usually reveals increased vascularity in and around the acutely inflamed appendix this examination is useful as an adjunct sign of appendicitis when appendiceal measurement is equivocal, in which it is uncertain as to whether the imaged appendix is normal or inflamed.^{2,7} Other ultrasonographically detectable alternative condition-gynaecological such as ovarian cyst, ectopic pregnancy, adnexal torsion and tubo- ovarian mass or abscess. Bacterial iliocaecitis, cholecystitis, perforated peptic

ulcer, urological condition, small bowel obstruction and caecal carcinoma.²

Modified Alvarado score is simple to use and easy to apply, when results of present study are compared with other studies, we observe that specificity, positive predictive value and negative appendectomy rate are comparable with that of the standard studies.^{2,9,10} But the sensitivity of the present study is better comparable to a study, as these studies are prospective studies.² Whereas compared with other studies which have shown low sensitivity as these studies were retrospective studies.^{9,10}

The present study has shown better sensitivity as it is a prospective study and shortcomings of retrospective study are ruled out. Modified Alvarado scoring system is a dynamic one allowing observation and critical evaluation of the clinical picture. Its application improved diagnostic accuracy and reduces negative exploration and complication rates. When ultrasonography results of the present study are compared to other standard studies, sensitivity, specificity, positive predictive value and diagnostic accuracy of the present study is almost comparable with that of standard studies.^{1,6,7,11}

When modified Alvarado score and ultrasonography were compared in terms of sensitivity, specificity, positive predictive value and diagnostic accuracy results are almost comparable. Neither one is significantly (100%) advantageous, but in cases where modified Alvarado score is negative or equivocal the addition of ultrasonography improves diagnostic accuracy specifically in females. Thus, this study goes on to prove ultrasonography adjunct value in suspected cases of acute appendicitis.

CONCLUSION

The modified Alvarado score can be used effectively in clinical decision making in our set up. When compared with ultrasonography neither one is 100% reliable and diagnostically accurate. However, additional information provided by ultrasonography improves diagnostic accuracy.

Funding: No funding sources

Conflict of interest: None declared

Ethical approval: The study was approved by the Institutional Ethics Committee

REFERENCES

1. Sharma R, Kasliwal DK, Sharma RG. Evaluation of negative appendectomy rate in cases of suspected acute appendicitis and to study the usefulness of ultrasonography in improving the diagnostic accuracy. *Indian J Surg.* 2007;69(5):194-7.
2. Kurane SB, Sangolli MS, Gogate AS. A one-year prospective study to compare and evaluate diagnostic accuracy of modified Alvarado score and ultrasonography in acute appendicitis, in adults. *Indian J Surg.* 2008;70(3):125-9.
3. Hlibezuk V, Dattarao JA, Jin Z, Falzon L, Brown MD. Diagnostic accuracy of non-contrast computed Tomography for appendicitis in adults. *Ann Emerg Med.* 2010;55:51-9.
4. Khan I, Rahaman AU. Application of Alvarado scoring system in diagnosis of acute appendicitis. *J. Ayub Medical College, Abotabad.* 2005;17:41-4.
5. Rao PM, Rhea JT, Novelline RA, Mostafavi AA, McCabe CJ. Effect of computed tomography of the appendix on treatment of patients and use of hospital resources. *New England J Med.* 1998;338(3):141-6.
6. Mardan MA1, Mufti TS, Khattak IU, Chilkunda N, Alshayeb AA, Mohammad AM, et al. Role of ultrasound in acute appendicitis, *J. Ayub Medical College Abotabad.* 2007;19:72-8.
7. Petroianu A. Diagnosis of acute appendicitis, *International J Surg.* 2012;10(2012):115-9.
8. Kalen M, Rich AJ, Talbot DR, Canlitie WJ. Evaluation of modified Alvarado score in the diagnosis of acute appendicitis a prospective study, *Ann R Coll Surg Engl.* 1994;76:418-9.
9. Shaha SWA, Khan CA, Malik SA, Waqas A, Tarrar AM, Bhutta IA. Modified Alvarado score: Accuracy in diagnosis of acute appendicitis in adults. *Prof Med J.* 2010;17:546-50.
10. Memon ZA, Irfan S, Fatima K, Iqbal MS, Sami W. Acute appendicitis diagnostic accuracy of Alvarado scoring system, *Asian J Surg.* 2013;36:144-9.
11. D'souza N, D'souza C, Grant D, Royston E, Farouk M. The value of ultrasonography in the diagnosis of appendicitis, *Int J Surg.* 2015;13(2015):165-9.

Cite this article as: Gaikwad MD, Auti A, Magare A. A three year prospective study-suspected acute appendicitis: diagnostic accuracy of modified Alvarado score versus ultrasonography in adults. *Int Surg J* 2017;4:3924-7.