

# A rare case of lateral ovotesticular disorder with Klinefelter syndrome mosaicism 46, XX/47, XXY: An unusual presentation

Shyam M. Talreja, Indraneel Banerjee, Sher Singh Yadav, Vinay Tomar

Department of Urology, SMS Medical College and Hospital, Jaipur, Rajasthan, India

## Abstract

Ovotesticular disorder of sex development (OT-DSD) is a rare disorder of sexual differentiation characterized by the presence of both ovarian and testicular tissues in the same individual. It's incidence ranges from 3% to 10% of all disorder of DSD's, and the most common presentation is 46, XX followed by 46, XX/46, XY mosaicism and 46, XY. Klinefelter syndrome (KS) mosaicism 46, XX/47, XXY is extremely rare, and its association with the ovotesticular disorder is even rarer. We report an unusual case of 16-year-old with male habitus who presented with complains of cyclic hematuria. On examination, he had bilateral gynecomastia, unilateral left cryptorchidism, absent facial hair, sparse axillary hair growth, and pubic hair distribution of feminine type. The right testis was of normal size located normally in hemiscrotum and was confirmed by radio imaging. Ultrasonography and magnetic resonance imaging revealed a cystic area behind posterior half of urinary bladder. Chromosomal analysis revealed 46, XX/47, XXY mosaicism of female karyotype and KS. Histopathological report of this left side excised specimen confirmed the structures to be ovary, uterus, and fallopian tube, thus confirming our diagnosis of the lateral ovotesticular disorder. Meticulous workup combined interdisciplinary approach will lead to early diagnosis and resolve timely sex reassignment issues and also prevent consequences arising due to gonadal insufficiency.

**Key Words:** 46XX/47XXY Klinefelter syndrome mosaicism, cyclic hematuria, ovotesticular disorder

## Address for correspondence:

Dr. Shyam M. Talreja, Department of Urology, SMS Medical College and Hospital, Jaipur - 302 004, Rajasthan, India. E-mail: talrejasmyam@gmail.com

**Received:** 17.04.2015, **Accepted:** 20.06.2015

## INTRODUCTION

Ovotesticular disorder of sex development (OT-DSD) is a rare disorder of sexual differentiation characterized by the presence of both ovarian and testicular tissues in the same individual. Both elements can be present in the same gonad (an ovotestis) or separately in the same individual or as unilateral ovotestis and other side testis or ovary.<sup>[1-3]</sup>

The incidence of OT-DSD ranges from 3% to 10% of all DSD.<sup>[1,3]</sup> Klinefelter syndrome (KS) mosaicism 46, XX/47, XXY is extremely rare, and its association with the ovotesticular disorder is even rarer. Only four cases of OT-DSD with KS mosaicism 46, XX/47, XXY have been reported till date to the best of our knowledge. Our case is the fifth-one.<sup>[4]</sup>

This is an open access article distributed under the terms of the Creative Commons Attribution-NonCommercial-ShareAlike 3.0 License, which allows others to remix, tweak, and build upon the work non-commercially, as long as the author is credited and the new creations are licensed under the identical terms.

**For reprints contact:** reprints@medknow.com

**How to cite this article:** Talreja SM, Banerjee I, Yadav SS, Tomar V. A rare case of lateral ovotesticular disorder with Klinefelter syndrome mosaicism 46, XX/47, XXY: An unusual presentation. *Urol Ann* 2015;7:520-3.

### Access this article online

#### Quick Response Code:



#### Website:

www.urologyannals.com

#### DOI:

10.4103/0974-7796.164855

## CASE REPORT

A 16-year-old with male habitus presented with complains of cyclic hematuria. The episodes of hematuria occurred monthly for a duration of 3–4 days since 6 months, which were always preceded by lower abdominal cramps. There was no antenatal hormonal or drug exposure, no history of precocious neonatal death in the family, ambiguous genitalia, genetic syndromes or any known endocrinopathy.

On physical examination, the patient was a thin built male with height 154 cm, weight 56 kg, normal intellectual function, and bilateral gynecomastia (Tanner stage 3). Facial hair was absent, and axillary hair growth was sparse. External genitalia examination revealed pubic hair of feminine distribution type (Tanner stage 3), penile length of 4 cm with normally located external meatus, and unilateral left cryptorchidism without a detectable hernia. The right side testis was of normal size and consistency normally located in the hemiscrotum. Digital rectal examination revealed smooth cystic swelling above small size prostate over the left half. The rest of the systemic examination was unremarkable [Figure 1a-c].

On ultrasonography, a cystic area of 42 mm × 32 mm was seen behind the left posterior half of urinary bladder with mild left sided hydroureteronephrosis. Magnetic resonance imaging findings were also consistent with ultrasonography report with no evidence of left side testis in the abdomen. The right side gonad was confirmed to be testis by radio imaging [Figure 1d and e].

Hormonal findings of the patient are depicted in Table I. The patient was subjected to chromosomal analysis (GTG banding with 500 band resolution) which revealed 46, XX/47, XXY

mosaicism of female karyotype and KS. Specimen studied was whole blood, and 50 cells were counted and analyzed. Of 50, 40 cells showed mosaicism 46, XX, and the remaining 10 cells showed 47, XXY [Figure 2a and b].

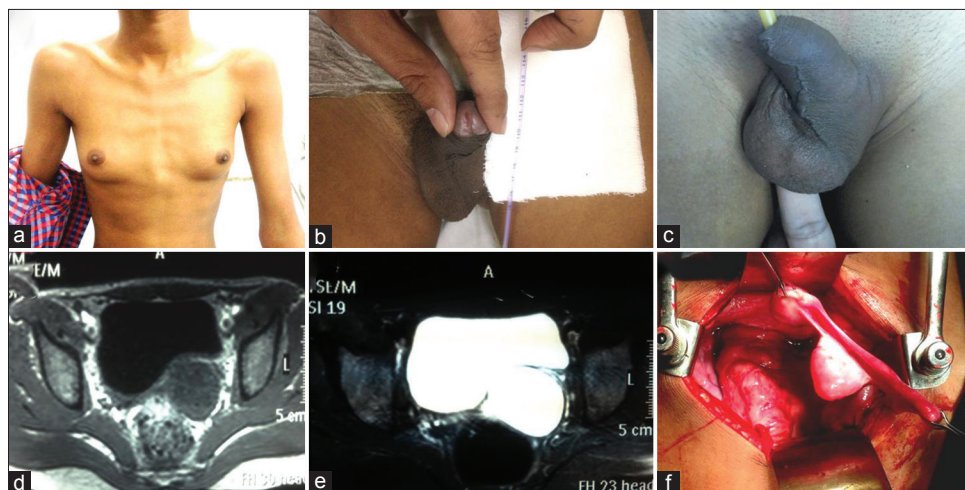
Subsequently, patient underwent cystoscopy during episode of hematuria, which revealed smooth walled bladder with a large bulge over the left half due to which left ureteric orifice was displaced superiorly and medially, and small size prostate with prominent verumontanum. Abdominal exploration through midline revealed a cystic swelling through which remnant of the uterus was attached to the prostatic urethra in the midline with single fallopian tube and ovary. [Figure 1f] These structures were excised in view of patient reared as male.

The histopathological report confirmed the excised structures to be ovary with cystic follicles, a uterus with endometrium in the proliferative phase and fallopian tube. Cystic swelling showed a few glandular structures with stratified squamous epithelium in cyst wall suggestive of the cervix [Figure 2c-g].

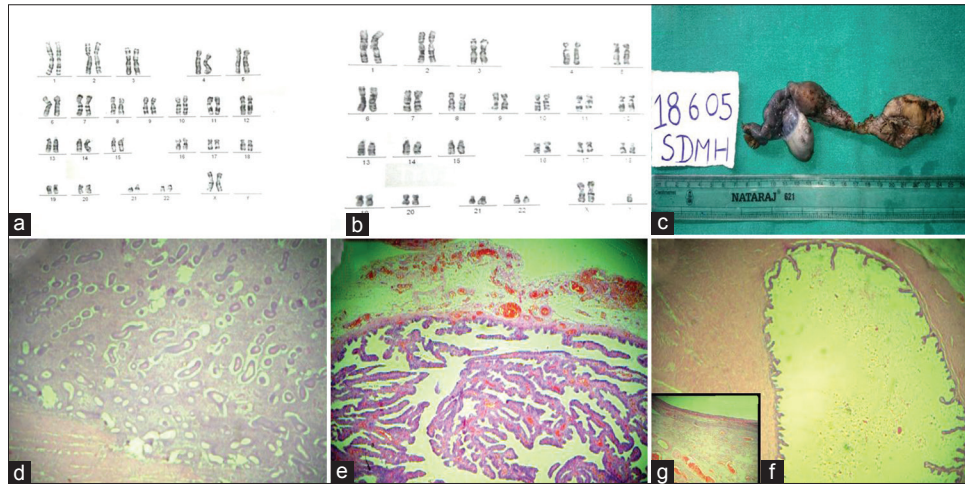
## DISCUSSION

OT-DSD is a rare entity, subdivided into three groups-unilateral OT-DSD having testis or ovary on one side and ovotestis on the other side. It is the most common presentation. Second is bilateral OT-DSD with ovotestis on both sides, and the third is lateral OT-DSD with ovary on one side (left side most common) and a testis on the other side (most commonly right side).<sup>[1,5,6]</sup>

Krob *et al.* studied 215 true hermaphrodites and found the following combination in decreasing order of their frequency-ovotestis and ovary, bilateral ovotestis, ovary and testis in same individual (lateral), and ovotestis and testis.<sup>[7]</sup>



**Figure 1:** (a) Bilateral gynecomastia. (b) A penis with the normally located urethral meatus. (c) Right testes in right hemiscrotum, (d and e) Magnetic resonance imaging pelvis T1- and T2-weighted images, respectively, showing cystic swelling behind the urinary bladder. (f) Intraoperative image showing female internal genitalia



**Figure 2:** (a and b) Chromosomal analysis (GTG banding) revealed mosaicism 46,XX/47,XXY. (c) Gross specimen consisting of rudimentary uterus and cervix with attached Fallopian tube and ovary. (d) Endometrial glands in proliferative phase, H and E, x100. (e) Micrograph showing the structure of the fallopian tube. Note the plica, H and E, x100. (f) Ovarian stroma and cystic follicle, H and E, x100. (g) Inset showing ovarian stroma and congested and dilated blood vessels, H, and E, x100

**Table 1: Hormonal assay of patient**

Hormones	Patient value (serum hormone levels)	Reference range
Testosterone, ng/dL	80.6	For male 20-49 years, 72-853
FSH, mIU/mL	1.56	0.7-11.1
LH, mIU/mL	2.04	0.8-7.6
Estradiol, pg/dL	142	11-44

FSH: Follicle stimulating hormone, LH: Luteinizing hormone

OT-DSD presents with different karyotypes, predominant of them being 46, XX followed by 46, XX/46, XY mosaicism and 46, XY.<sup>[1,3,8]</sup>

Krob *et al.* studied 228 cases for chromosomal analysis and found 46, XX as the most common karyotype (70.6%) followed by 46, XX/46, XY mosaicism (20.2%) and 46, XY (7%).<sup>[7]</sup>

OT-DSD has varied presentations ranging from ambiguous genitalia to a normal female or male phenotype.<sup>[1,2,6]</sup>

Our patient presented with cyclic hematuria preceded by lower abdominal pain, which lasted 2–3 days. This hematuria corresponded to the monthly flow of menstruation. Histological confirmation is must for diagnosis of OT-DSD.<sup>[1]</sup> In our case, a biopsy revealed endometrial glands in proliferative phase which suggested an estrogenic effect on the endometrium. The histopathological examination also revealed ovarian tissue along with fallopian tube structure in the excised specimen. The right testis was radiologically confirmed in its normal position. Thus, the presence of both ovarian and testicular tissue in the same individual confirmed the diagnosis of the ovotesticular disorder.

Apart from physical, radiological, and histopathological examination; hormonal assays and chromosomal analysis are

also very important in the evaluation of patients with. These tests help in karyotype typing of affected individuals, leading way for proper management.

This patient had gynecomastia, one of the features of KS. His chromosomal analysis displayed 46, XX/47, XXY mosaicism, which is a very rare presentation of KS. KS with an incidence of 1 in 500 newborn males is the most common human sex chromosomal abnormality.<sup>[4]</sup> Features suggestive of KS are gynecomastia, hypogonadism, azoospermia or oligospermia, slim built, increased height, long fingers, low testosterone, and increased levels of gonadotropins. The most common karyotype in KS is 47XXY.<sup>[4]</sup> Velissariou *et al.* in their study reported that 47, XXY/46, XX mosaicism is immensely rare and till date has been reported in only four cases of ovotesticular disorder and five cases of patients with features suggestive of KS.<sup>[4]</sup>

There have been studies reporting the low risk of malignancy in patients with the ovo-testicular disorder. Pleskacova *et al.* have estimated the risk of malignancy at 2.6% whereas Sircili *et al.* reported the risk to be lying in between 2.6% and 4.6%.<sup>[6,9]</sup>

KS patients have increased the risk of developing malignancy especially mediastinal germ cell tumors which makes follow-up in these patients essential. Song *et al.* have reported the risk of extragonadal germ cell tumors in young males with KS to be 66.7%.<sup>[10]</sup>

**CONCLUSION**

Association of lateral ovotesticular disorder with KS 46, XX/47, XXY requires an interdisciplinary approach for early

diagnosis to resolve sex reassignment issues. Regular follow-up is necessary to prevent consequences arising due to gonadal insufficiency and inherent risk of malignancy.

### Financial support and sponsorship

Nil.

### Conflicts of interest

There are no conflicts of interest.

### REFERENCES

1. Ozsu E, Mutlu GY, Cizmecioglu FM, Ekingen G, Muezzinoglu B, Hatun S. Ovotesticular disorder of sexual development and a rare 46, XX/47, XXY karyotype. *J Pediatr Endocrinol Metab* 2013;26:789-91.
2. Isguven P, Yildiz M, Arslanoglu I, Adal E, Erguven M, Tuzlali S. True hermaphroditism with characteristics of Klinefelter's syndrome: A rare presentation. *J Pediatr Endocrinol Metab* 2005;18:603-6.
3. Wettasinghe KT, Sirisena ND, Andraweera PH, Jayasekara RW, Dissanayake VH. A case series of five Sri Lankan patients with ovotesticular disorder of sex development. *Clin Pediatr Endocrinol* 2012;21:69-73.
4. Velissariou V, Christopoulou S, Karadimas C, Pihos I, Kanaka-Gantenbein C, Kapranos N, *et al.* Rare XXY/XX mosaicism in a phenotypic male with Klinefelter syndrome: Case report. *Eur J Med Genet* 2006;49:331-7.
5. Luy SC, Ho F. A rare case of true hermaphrodite with features of Klinefelter syndrome. *Philipp J Intern Med* 2013;51:1-9.
6. Sircili MH, Denes FT, Costa EM, Machado MG, Inacio M, Silva RB, *et al.* Long-term followup of a large cohort of patients with ovotesticular disorder of sex development. *J Urol* 2014;191:1532-6.
7. Krob G, Braun A, Kuhnle U. True hermaphroditism: Geographical distribution, clinical findings, chromosomes and gonadal histology. *Eur J Pediatr* 1994;153:2-10.
8. Kanaka-Gantenbein CH, Papandreou E, Stefanaki K, Fryssira H, Kolialexi A, Sophocleous C, *et al.* Spontaneous ovulation in a true hermaphrodite with normal male phenotype and a rare 46, XX/47, XXY Klinefelter's mosaic karyotype. *Horm Res* 2007;68:139-44.
9. Pleskacova J, Hersmus R, Oosterhuis JW, Setyawati BA, Faradz SM, Cools M, *et al.* Tumor risk in disorders of sex development. *Sex Dev* 2010;4:259-69.
10. Song JS, Lee SH, Jin DK, Kim SH. A case report of rare XXY/XX mosaicism in a phenotypic male with Klinefelter syndrome and mediastinal germ cell tumor. *Genet Couns* 2014;25:215-20.