

Received: 2014.09.11
Accepted: 2014.11.17
Published: 2015.02.26

ISSN 1941-5923
© Am J Case Rep, 2015; 16: 115-118
DOI: 10.12659/AJCR.892456

Inadvertent Transmission of Polycystic Kidney Disease in Kidney Transplantation

Authors' Contribution:
Study Design A
Data Collection B
Statistical Analysis C
Data Interpretation D
Manuscript Preparation E
Literature Search F
Funds Collection G

BEF 1 **Amit Langote***
BEF 1 **Andrea Mazarova***
A 2 **John Mahoney**
A 2 **Brian Blew**
ACEF 1,3 **Greg A. Knoll**

1 Division of Nephrology, Department of Medicine, Ottawa Hospital, Ottawa, ON, Canada
2 Division of Urology, Department of Surgery, Ottawa Hospital, Ottawa, ON, Canada
3 Scientist, Ottawa Hospital Research Institute, Ottawa, ON, Canada

Corresponding Author:
Conflict of interest:

* Amit Langote and Andrea Mazarova contributed equally to this manuscript

Amit Langote, e-mail: drlangoteamit@gmail.com

None declared

Patient: **Male, 55**
Final Diagnosis: **Polycystic transformation of transplant kidney**
Symptoms: **Hematuria**
Medication: **Tacrolimus • Mycophenolate Mofetil • Prednisone**
Clinical Procedure: **Graft nephrectomy**
Specialty: **Nephrology**

Objective: **Unusual clinical course**

Background: Although organ donors are rigorously tested, occasionally an unidentified donor disease can be transmitted to the recipient. These conditions include malignancies, infections, and, rarely, congenital diseases.





Case Report: We report a case of an inadvertent transmission of polycystic kidney disease from a 40-year-old trauma victim to both kidney recipients. There was no family history of renal disease in the donor. The renal allografts gradually increased in size with the development of cysts and functioned for 10 and 14 years.

Conclusions: We report a case of inadvertent transmission of polycystic kidney disease from an unsuspecting deceased donor to both the recipients through renal allograft. Both the grafts lasted long enough to suggest that polycystic kidneys from deceased donors can be considered for transplantation.

MeSH Keywords: **Kidney Transplantation • Polycystic Kidney Diseases • Tissue Donors • Unrelated Donors**

Abbreviations: **ESRD – end-stage renal disease; PKD – polycystic kidney disease**

Full-text PDF: <http://www.amjcaserep.com/abstract/index/idArt/892456>

 1272   2  10



Background

We describe an interesting case in which a 40-year-old male trauma victim, without a confirmed or suspected diagnosis of polycystic kidney disease (PKD), transmitted the condition to 2 recipients in the setting of organ transplantation. To our knowledge, this is the first published case report on inadvertent transmission of PKD to both recipients, who were followed throughout the post-transplant period until their kidney allografts failed.

Cases Report

Case 1

The recipient was a Caucasian man who developed end-stage renal disease (ESRD) in 1983 at the age of 24 years due to necrotizing glomerulonephritis. His first renal transplant (1988) failed after 10 years to severe necrotizing fasciitis. In 1998, he received his second renal transplant from a healthy 40-year-old man with no family history of renal disease who died following a motor vehicle accident. There were no gross abnormalities in the kidney noted by the surgeon at the time of implantation. His immediate post-operative ultrasound showed that the renal allograft was 12.1 cm in length with a 2 cm cyst in the mid-portion of the posterior cortex and a 1-cm adjacent cortical cyst. His immunosuppression included tacrolimus, prednisone, and mycophenolate mofetil. The transplant worked well for the first 4 years with a serum creatinine that fluctuated between 1.4 and 1.8 mg/dl.

In 2001, a renal biopsy was performed because of worsening of graft function (serum creatinine 2.6 mg/dl) that revealed a Banff IA acute tubulointerstitial rejection. Pre-biopsy ultrasound showed a 12-cm graft with multiple simple cysts throughout the renal parenchyma, the largest measuring 2.8×2.5 cm. The rejection was treated successfully; he had an uneventful course for a decade, with a stable creatinine of approximately 1.7 mg/dl.

In 2012, the patient developed pneumocystis pneumonia and acute allograft dysfunction. On ultrasound, the transplanted kidney had increased to 15.6 cm with multiple cortical cysts (largest 4.1×4 cm), essentially replacing the entire renal parenchyma (Figure 1). He was eventually re-started on maintenance hemodialysis. One year later, he underwent graft nephrectomy because of persistent hematuria. Gross examination of the nephrectomy specimen revealed innumerable cystic spaces, which ranged from 0.2 to 2.5 cm in diameter, occupying almost the entire parenchyma, leaving only a small rim of cortex. Histological examination revealed numerous simple cysts of variable size, including quite large cysts, which were compatible with polycystic kidney disease.

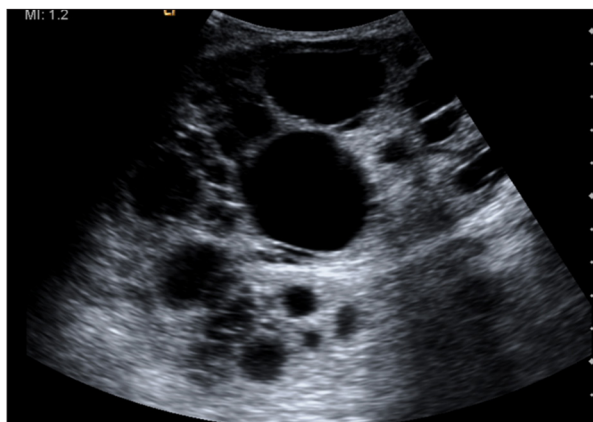


Figure 1. Ultrasound image from Case 1 showing multiple cortical cysts replacing the entire renal parenchyma of the transplant kidney.

Case 2

The second recipient was a Caucasian man with bipolar disorder who developed lithium-induced chronic interstitial nephritis and ESRD in 1996 at the age of 57 years. In 1998 he received a deceased donor renal transplant from the same donor as in Case 1. Again, there were no gross abnormalities noted on the kidney at the time of implantation. Ultrasound performed post-operatively revealed a transplant kidney measuring 11.3 cm in length with a 1.7 cm cortical and a 1.8 cm parapelvic cyst. His graft eventually functioned and his serum creatinine levelled off at approximately 1.8 mg/dl. His immunosuppression regimen consisted of cyclosporine, mycophenolate mofetil, and prednisone.

From 2000 onwards he developed microscopic hematuria and in 2001 his allograft function slowly began to deteriorate. In 2004 a renal biopsy was performed, which showed severe arteriolar hyalinosis and moderate interstitial fibrosis. At the time of ultrasound-guided biopsy, no comment was made about the presence of cysts in the transplanted kidney. His renal function gradually deteriorated and he resumed dialysis in 2008. No renal imaging was performed between 2004 and 2008. In 2009 an abdominal ultrasound was repeated, which showed that the allograft was 11.2 cm, and the renal parenchyma was replaced with multiple simple cortical cysts (Figure 2). In 2010 the patient developed gross hematuria and abdominal CT showed a complex cystic mass arising from the allograft. Because the differential diagnosis included lymphoma and renal cell carcinoma, graft nephrectomy was considered, but the patient declined. A follow-up ultrasound in 2011 showed an increase in allograft size to 13.4 cm, multiple cysts throughout the kidney transplant, and regression of the mass, which now had features consistent with a necrotic hemorrhagic cyst. After we made the connection between these 2 cases, we contacted the organ procurement organization for further

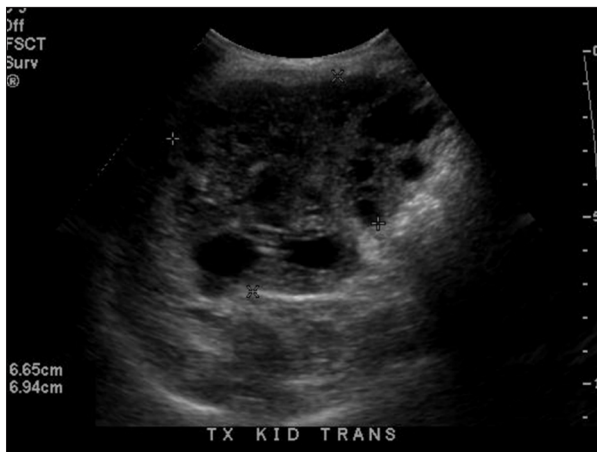

Figure 2. Ultrasound image from Case 2 showing multiple cysts throughout the kidney transplant replacing the normal renal parenchyma.

information about the donated liver but no information was available noting whether there were hepatic cysts.

Discussion

We present a case report on 2 kidney transplant recipients with inadvertent transmission of PKD from the donor. In both cases, the allografts gradually increased in size with increasing numbers of cysts. However, both renal grafts functioned for a reasonably long time. Although we did not have genetic testing results to confirm the diagnosis, we believe these cases represent the transplantation of kidneys affected with PKD. First, it is uncommon for a 40-year-old to have 2 cysts in each kidney, as was seen in our donor [1,2]. This suggests, in retrospect, that the donor kidneys were not normal at the time of transplantation. Second, both transplanted kidneys eventually became enlarged. This is a classical discriminating feature of PKD that is not seen in acquired cystic disease, which would be the other possible diagnosis in this case. Third, many of the renal cysts were quite large, which is also consistent with PKD and not with acquired cystic disease, in which most cysts are <0.5 cm. Also, multiple renal cysts were identified at the time of dialysis initiation or shortly thereafter. In acquired cystic disease, this degree of cyst development would only be seen after many years of dialysis. And finally, histopathology test results in Case 1 were consistent with a PKD diagnosis.

To the best of our knowledge, there is only 1 previous report on inadvertent transmission of PKD to both kidney recipients

[3]. The donor was a 30-year-old man who died due to rupture of an intracranial aneurysm. There was no clinical evidence of kidney disease in either the donor or his family. However, both recipients gradually developed PKD phenotype in their renal grafts. Subsequently, the donor's genetic testing results confirmed a novel PKD1 mutation. Both grafts functioned well during the entire 5-year follow-up period. In our report, both recipients were followed until after their grafts failed.

Although each deceased donor kidney had 2 cortical cysts described on the post-implantation ultrasound, there were no gross abnormalities noted on either kidney at the time of transplantation. Moreover, the donor's family history was negative for PKD. Therefore, at the time of transplantation there was no knowledge or even suspicion of PKD in the donor. From several reported cases involving the known transplantation of donors with polycystic kidney disease [4–10], only 1 case reached ESRD due to progressive cyst development 12.5 years after renal transplantation [4]. Notably, the other patients were not followed until their transplanted kidneys failed. Therefore, it is reasonable to believe that the PKD (autosomal dominant type)-affected allograft can last approximately 10–15 years if transplanted from a donor with early-stage disease. This was confirmed even by our cases, where the allografts functioned for 14 and 10 years.

Conclusions

We report a case of inadvertent transmission of PKD to both patients who received renal allografts from the same deceased donor. Despite rigorous donor screening, the transmission of a hereditary disease such as PKD can inadvertently occur.

Strengths

1) Both of the transplant recipients were followed from the time of transplantation until graft failure; hence, all details about their case are available to make necessary comparisons and trace them to the same donor. 2) Histopathology results support the diagnosis of PKD in the graft in Case 1.

Limitations

1) We did not conduct genetic studies to confirm polycystic disease in the renal allografts. 2) There were only a limited number of renal ultrasounds performed before the allografts failed and no high-resolution ultrasound or magnetic resonance imaging was done.

References:

1. Clayman RV, Surya V, Miller RP et al: Pursuit of the renal mass. Is ultrasound enough? *Am J Med*, 1984; 77(2): 218–23
2. Pei Y, Hwang Y, Conklin J et al: Imaging-based diagnosis of autosomal dominant polycystic kidney disease. *J Am Soc Nephrol*, 2014; pii: ASN.2014030297 [Epub ahead of print]
3. Canaud G, Knebelmann B, Harris PC et al: Therapeutic mTOR inhibition in autosomal dominant polycystic kidney disease: What is the appropriate serum level? *Am J Transplant*, 2010; 10(7): 1701–6
4. Howard RJ, Reed AI, Van der Werf WJ et al: Development of polycystic disease in a kidney 10 years after transplantation. *Transplantation*, 1999; 68(10): 1620
5. Siegal B: The polycystic kidney donor. *Transplantation*, 1992; 54(6): 1131
6. Mancini G, Comparini L, Salvadori M: Transplant of a polycystic kidney because of organ shortage. *Transplant Proc*, 1990; 22(2): 376
7. Spees EK, Orlowski JP, Schorr WJ et al: Successful use of polycystic cadaver donor kidneys. *Transplant Proc*, 1990; 22(2): 374–75
8. Shan YS, Lee PC, Sy ED et al: Polycystic kidney patient as a cadaveric donor: is it appropriate? *Nephrol Dial Transplant*, 2001; 16(2): 410–11
9. Olsburgh JD, Godbole HC, O'Donnell PJ et al: Transplantation of kidneys from deceased adult polycystic donors. *Am J Transplant*, 2006; 6(11): 2809–11
10. Eng MK, Zorn KC, Harland RC et al: Fifteen-year follow-up of transplantation of a cadaveric polycystic kidney: a case report. *Transplant Proc*, 2008; 40(5): 1747–50