

# Percutaneous vertebroplasty in painful refractory vertebral hemangiomas

RV Narayana, Rajesh Pati, Sibasankar Dalai<sup>1</sup>

## ABSTRACT

**Background:** Painful vertebral hemangiomas are often inadequately managed medically. We evaluated the outcome of percutaneous vertebroplasty (PVP) in the treatment of painful vertebral hemangiomas refractory to medical management.

**Materials and Methods:** 14 patients (four thoracic and ten lumbar vertebra) with painful vertebral hemangiomas presenting with severe back pain for more than 6 months not responding to medical therapy were treated by vertebroplasty. Cross sectional imaging of the spine with magnetic resonance was done. Blood investigations were done to exclude coagulopathy excluded. PVP was performed under local anesthesia.

**Results:** The pain intensity numeric rating scale (PI-NRS-11) of these patients was in the range of 7-10 (Severe Pain). After vertebroplasty 8 patients were completely free of pain (PI NRS Score 0) while 6 were significantly relieved (PI-NRS Score 1-3). No complications were observed. Two patients with associated radicular pain had good pain relief following PVP. No recurrence was found during 36 months of postoperative followup.

**Conclusion:** PVP is a safe and effective procedure in patients with painful vertebral hemangiomas refractory to medical management.

**Key words:** Hemangioma, polymethyl methacrylate, percutaneous vertebroplasty

## INTRODUCTION

Vertebral hemangiomas are benign, malformed vascular tumors composed of newly formed blood vessels with normal capillary, venous, or veno-capillary structure and without arterio-venous shunt. They primarily involve the vertebra and may extend to the epidural space. There are two microscopic types of vertebral hemangiomas which frequently coexist. They are cavernous and capillary hemangiomas. Cavernous hemangiomas are composed of large dilated blood vessels closely clustered together and hence they are not separated by normal bone tissue. Capillary hemangiomas are formed of thin walled

capillary vessels of various sizes separated by normal bone tissue.<sup>1</sup>

Percutaneous vertebroplasty (PVP) is the procedure of injecting bone cement i.e. polymethyl methacrylate (PMMA) percutaneously into the vertebral body under fluoroscopic guidance. PVP was developed in France in the late 1980s, principally for treatment of vascular bone lesions such as hemangioma and subsequently found to be useful in treating painful vertebral metastasis and painful osteoporotic vertebral compression.<sup>2,4</sup> After introduction of PVP in North America, the procedure has become increasingly popular during the past decade. PVP has proven successful in providing dramatic and prompt pain relief in most patients with painful vertebral hemangioma, allowing rapid patient mobilization.

## MATERIALS AND METHODS

The spinal magnetic resonance imaging was studied in detail. Pathologies other than vertebral hemangiomas were excluded. 14 patients with vertebral hemangiomas, four had associated vertebral osteoporotic compression fracture, presented between November 2006 and April 2013, were included in the study. Back pain was diagnosed by the patient's history, clinical examination and quantified by pain intensity numeric rating scale (PI-NRS) [Table 1].<sup>5</sup> Patients' previous medical records and imaging were reviewed.

Departments of Neurology, <sup>1</sup>Interventional Neuroradiology, Seven Hills Hospital, Visakhapatnam, Andhra Pradesh, India

**Address for correspondence:** Dr. Sibasankar Dalai  
OP No: 12, First Floor, Seven Hills Hospital, Rockdale Layout,  
Visakhapatnam - 530 017, Andhra Pradesh, India.  
E-mail: sibasankar@gmail.com

Access this article online	
Quick Response Code:	Website: www.ijoonline.com
	DOI: 10.4103/0019-5413.128759

Based on the history and clinical findings, relevant imaging including magnetic resonance (MR) was done [Figure 1a].

The MR of the above 14 patients were normal except for vertebral hemangiomas in all and osteoporotic vertebral fractures in four of them. Bone densitometry and isotope bone scanning were not done.

Routine blood investigations for all these patients were done. Patients with low platelet count and coagulopathy were excluded. Patients with vertebral hemangiomas with severe back pain for more than 6 months, not responding to medical therapy were included in the study. All these patients received adequate analgesic therapy with two or more analgesics for more than 6 months. Informed, written consent obtained from all patient undergoing vertebroplasty after explaining the procedure in detail.

Patients were given 1.0 g of ceftriaxone intravenously 1 h prior to the procedure. All vertebroplasties were performed in the cathlab under high quality fluoroscopic guidance with patient positioned prone. The entire spine was examined with fluoroscopy in antero-posterior (AP) and lateral view and the level of hemangioma was marked with a metallic marker. The site of entry and the needle track was infiltrated with 10 ml of 2% xylocaine. The vertebra was approached with an 11G or 13G beveled cook bone biopsy needle from the trans-pedicular route. The needle was progressed into the vertebral body and positioned near the midline, approximately at the junction of the anterior one-third with the posterior two-third. The patient is asked to report any

pain or discomfort especially in the ipsilateral leg during the progression of the needle from the skin to vertebra. AP and lateral fluoroscopic views confirmed the position of the needle [Figure 1b]. The bone cement (PMMA) is cooled to 4-8° centigrade 1 h prior to injection. The cement is prepared by mixing PMMA powder and liquid PMMA (Cook Medical Inc., USA) and is filled into 1 cc glass syringes then injected into the vertebra through the bone biopsy needle under constant fluoroscopic guidance in Lateral view. As we inject, the cement fills the vertebra backward and we keep injecting till the cement comes to the posterior fourth of the vertebra [Figure 1c]. Keeping a close watch on the movement of the cement is critical to avoid extra vasation either into the venous system, foramina, or other extra vertebral sites. Leakage of cement leads to compression of adjacent structures like spinal nerve roots, spinal cord and may lead to neurological deficits. We inject around 4-7 cc of cement into each vertebra.<sup>6-8</sup> The cement injection is completed within 60-90 s as the PMMA polymerizes in quick time. The needle is removed and the site of entry is secured. Patient is discharged from the hospital on the next day of the procedure.

## RESULTS

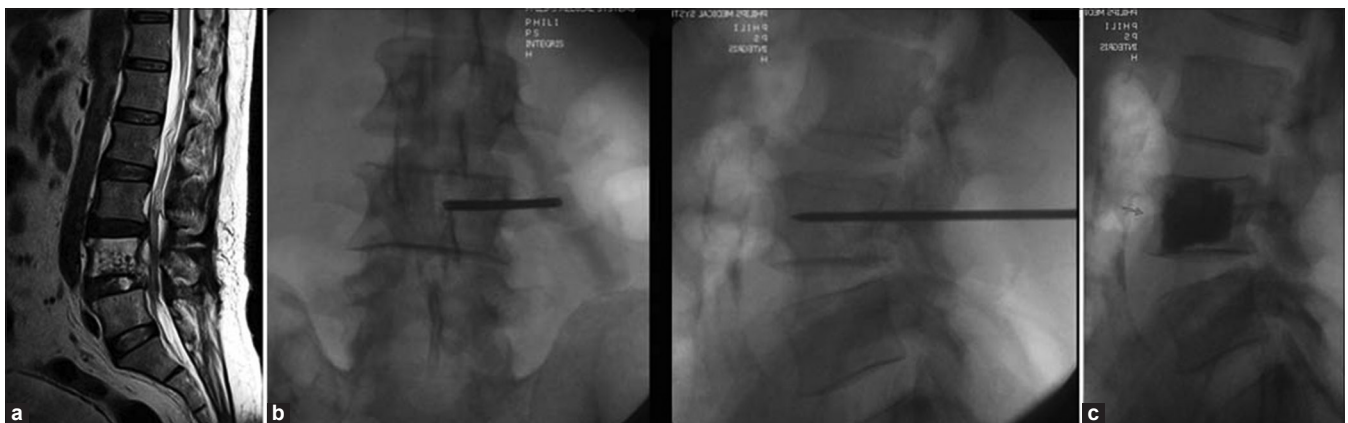
We treated 14 patients of vertebral hemangioma with PVP. Among these patients, five were males and nine females. The average age of patients was 68 years (range 24-79 years). All these patients were evaluated clinically and with 11-point PI numerical rating scale. Their average pain score was 8.5 (range 7-10) [Table 2].

After vertebroplasty pain was completely relieved in 8 (PI-NRS Score 0), and significantly relieved in 6 (PI-NRS Score 1-3) without any complications. Two patients with associated radicular pain had good pain relief following PVP. No recurrence was found during 36 months of postoperative followup.

**Table 1: The pain intensity NRS (0-10)**

Rating	Pain Level
0	No pain
1-3	Mild pain (nagging, annoying, interfering little with (ADLs))
4-6	Moderate pain (interferes significantly with ADLs)
7-10	Severe pain (disabling, unable to perform ADLs)

ADL = Activity of daily living, NRS = Numeric rating scale



**Figure 1:** (a) Magnetic resonance imaging T2W sagittal view showing L4 vertebral hemangioma (b) Needle position under fluoroscopy (antero-posterior and lateral view), (c) Lateral view fluoroscopy after vertebroplasty demonstrating good cement filling

Four patients had associated painful osteoporotic vertebral collapse. These patients were simultaneously treated with PVP in the same sitting without any complication [Figure 2a-c]. Up to three level vertebrae can be safely treated with PVP in the same sitting. As the amount of PMMA injected into the vertebra is so small, that even if 3 level PVP does not pose a significant risk.<sup>9</sup>

We had complex situations in two of our patients who underwent trans arterial embolization with poly vinyl particle polyvinyl alcohol (PVA) prior to vertebroplasty. During attempted vertebroplasty in one of them, the cement started leaking into the epidural vein without opacifying the vertebra. This was immediately identified and the procedure was postponed. The hemangioma was embolized and vertebroplasty was done in the next sitting [Figure 3a-c]. The other patient presented with pain and paraparesis in her early postpartum period. Cross sectional imaging demonstrated

D4 vertebral hemangioma with extra vertebral extension. She underwent trans-arterial embolization, vertebroplasty followed by laminectomy with a favorable outcome.

All the patients underwent immediate post procedure CT scan following vertebroplasty to look for cement leak to extra vertebral sites or fracture. These patients were followed up for 6-36 months with an average of 9 months with no recurrence of pain or any other complication.

## DISCUSSION

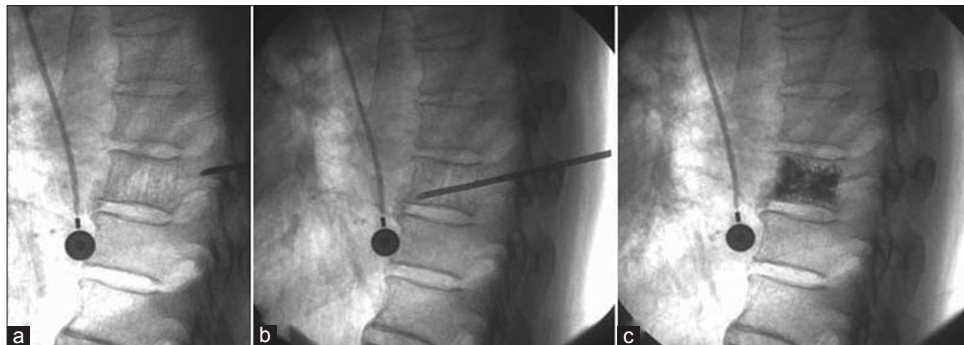
The true incidence of vertebral hemangiomas is not known. Different series have reported the incidence of vertebral hemangioma to be 10-27% based on autopsy series and imaging reviews. They are more common in females compared with males. Multiple hemangiomas are seen in 33% of the cases. The most common presentation in vertebral hemangioma patients is midline spinal pain. Otherwise most of them are asymptomatic. They required to be treated when they are symptomatic. They should be treated conservatively with analgesics and bed rest for at least 6 weeks. If they do not respond to the above therapies, more aggressive therapies such as surgical decompression, endovascular embolization, radiotherapy and vertebroplasty can be offered. Sometimes a combination of these therapies may be required.

Embolization with PVA particle alone is reported to produce usually transient remissions.<sup>10-12</sup> Two patients in this series underwent embolization with PVA particles followed by vertebroplasty. These two patients were taken for vertebroplasty in a usual manner. However, during injection of PMMA, the bone cement flew off into the epidural venous plexus, suggesting the blood flow to be very high inside the vertebra. Hence, the procedures were abandoned and embolization was done in these patients to reduce excess vascularity. vertebroplasty was done safely in these patients after embolization in a separate sitting. These patients had

**Table 2: List of patients underwent vertebroplasty**

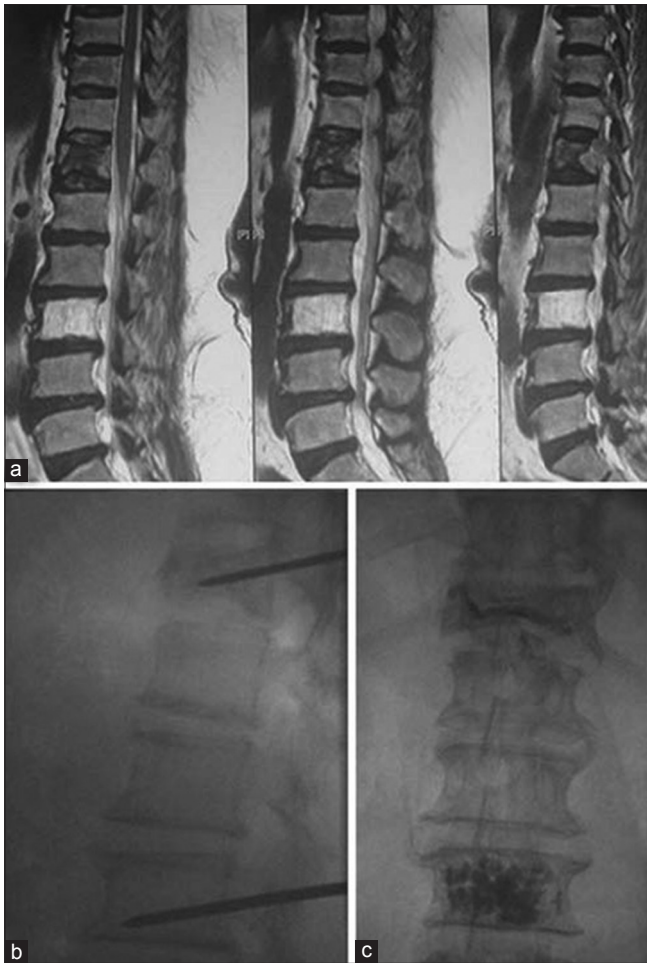Sl No.	Age	Sex	Level	Pain score	
				Pre PVP	Post PVP
1	60	F	D12 osteoporosis L3 hemangioma	9	0
2	79	M	D10 hemangioma	8	2
3	75	F	L1 hemangioma	8	1
4	45	F	L3 hemangioma	7	0
5	49	F	D10 hemangioma	9	0
6	47	F	L2 hemangioma	8	0
7	78	F	D9 osteoporosis L1 hemangioma	10	3
8	64	F	D11 and L1 osteoporosis D12 hemangioma	10	1
9	59	M	L2 hemangioma	9	0
10	24	F	D4 hemangioma	7	2
11	53	M	L1 hemangioma	9	0
12	74	M	L2 hemangioma	8	0
13	73	M	L2 hemangioma	8	0
14	71	F	D12 osteoporosis L2 hemangioma	9	2

PVP = Percutaneous vertebroplasty



**Figure 2:** (a) Fluoroscopic view (lateral) showing vertebral hemangioma with trabeculations. (b) Needle position. (c) Radiograph post vertebroplasty





**Figure 3:** (a) Magnetic resonance imaging T2W sagittal view showing L3 vertebral hemangioma and osteoporotic compression fracture of D12, (b) Fluoroscopic view demonstrating needle position, (c) Vertebroplasty of L3 hemangioma and osteoporotic D12 vertebra

a good short term and long term outcome. Angiogram may not be performed in all patients of vertebral hemangiomas before vertebroplasty. However, if the bone cement flies off the vertebra during injection due to high flow, the procedure must be abandoned and angio-embolization may be done before reattempting vertebroplasty.

Radiation therapy can be used to treat lesions associated with pain.<sup>23</sup> They are radiosensitive lesions and respond to administration of 3000-4000 cGy. Yang *et al.*,<sup>13</sup> and Faria *et al.*,<sup>14</sup> in their study have reported complete reversal of paraplegia of several weeks duration following radiation therapy alone. Radiation therapy as the sole management modality for patients with progressive neurological deficits has however, been controversial.

Vertebroplasty has a low rate of clinical complications, but potential complications can be devastating. Cement extravasation is one of the possible complications of vertebroplasty. Incidences of cement leakage are less in hemangioma due

to intact cortex compared with osteoporotic fracture. The leakage of cement can be into any structure around the vertebra. The relevance of this complication will be different in relation to the anatomical structure, which is invaded from the cement. Cement invasion into the vena cava, lungs, heart have been described.<sup>15,16</sup> These major adverse events only occur in less than 1% of the patients,<sup>17</sup> and require immediate management.

PVP can be performed through unipedicular or bipedicular approach. However, in most instances a single injection through one pedicle is all that is required.<sup>18,19</sup> If there is insufficient filling of the vertebral bodies, a second puncture through the contralateral pedicle may be performed. We performed PVP through unipedicular approach in all our patients. A total of 14 patients with vertebral hemangiomas treated by unipedicular PMMA injection, pain is completely relieved in 8 cases (PI-NRS Score 0) and significantly relieved in 6 cases (PI-NRS Score 1-3). High quality fluoroscopy and operator experience are important to avoid complications like neurologic deficits, fracture of vertebra and rib, hemorrhage, pneumothorax or hemothorax, and pulmonary embolus.<sup>20-22</sup>

We conclude that it is possible to treat painful vertebral hemangioma at single or multiple vertebral levels with or without vertebral collapse in the same sitting with excellent clinical outcome. Vertebral hemangiomas with high flow needs angio-embolization before a vertebroplasty.

## REFERENCES

1. Gray F, Gherardi R, Benhaïem-Sigaux N. Vertebral hemangioma. Definition, limitations, anatomopathologic aspects. *Neurochirurgie* 1989;35:267-9.
2. Galibert P, Deramond H, Rosat P, Le Gars D. Preliminary note on the treatment of vertebral angioma by percutaneous acrylic vertebroplasty. *Neurochirurgie* 1987;33:166-8.
3. Kaemmerlen P, Thiesse P, Bouvard H, Biron P, Mornex F, Jonas P. Percutaneous vertebroplasty in the treatment of metastases. *Technic and results. J Radiol* 1989;70:557-62.
4. Kaemmerlen P, Thiesse P, Jonas P, Bérard CL, Duquesnel J, Bascoulegue Y, *et al.* Percutaneous injection of orthopedic cement in metastatic vertebral lesions. *N Engl J Med* 1989;321:121.
5. Turk DC, Rudy TE, Sorkin BA. Neglected topics in chronic pain treatment outcome studies: Determination of success. *Pain* 1993;53:3-16.
6. Lin DD, Gailloud P, Murphy KJ. Percutaneous vertebroplasty in benign and malignant disease. *Neurosurg Q* 2002;11:290-301.
7. Cotten A, Dewatre F, Cortet B, Assaker R, Leblond D, Duquesnoy B, *et al.* Percutaneous vertebroplasty for osteolytic metastases and myeloma: Effects of the percentage of lesion filling and the leakage of methyl methacrylate at clinical followup. *Radiology* 1996;200:525-30.
8. Belkoff SM, Mathis JM, Jasper LE, Deramond H. The biomechanics of vertebroplasty. The effect of cement volume

- on mechanical behavior. *Spine (Phila Pa 1976)* 2001;26:1537-41.
9. Kaufmann TJ, Jensen ME, Ford G, Gill LL, Marx WF, Kallmes DF. Cardiovascular effects of polymethylmethacrylate use in percutaneous vertebroplasty. *AJNR Am J Neuroradiol* 2002;23:601-4.
  10. Gross CE, Hodge CH Jr, Binet EF, Kricheff II. Relief of spinal block during embolization of a vertebral body hemangioma. Case report. *J Neurosurg* 1976;45:327-30.
  11. Smith TP, Koci T, Mehringer CM, Tsai FY, Fraser KW, Dowd CF, *et al.* Transarterial embolization of vertebral hemangioma. *J Vasc Interv Radiol* 1993;4:681-5.
  12. Raco A, Ciappetta P, Artico M, Salvati M, Guidetti G, Guglielmi G. Vertebral hemangiomas with cord compression: The role of embolization in five cases. *Surg Neurol* 1990;34:164-8.
  13. Yang ZY, Zhang LJ, Chen ZX, Hu HY. Hemangioma of the vertebral column. A report on twenty three patients with special reference to functional recovery after radiation therapy. *Acta Radiol Oncol* 1985;24:129-32.
  14. Faria SL, Schlupp WR, Chiminazzo H Jr. Radiotherapy in the treatment of vertebral hemangiomas. *Int J Radiat Oncol Biol Phys* 1985;11:387-90.
  15. Quesada N, Mutlu GM. Images in cardiovascular medicine. Pulmonary embolization of acrylic cement during vertebroplasty. *Circulation* 2006;113:e295-6.
  16. Barragán-Campos HM, Vallée JN, Lo D, Cormier E, Jean B, Rose M, *et al.* Percutaneous vertebroplasty for spinal metastases: Complications. *Radiology* 2006;238:354-62.
  17. Nussbaum DA, Gailloud P, Murphy K. A review of complications associated with vertebroplasty and kyphoplasty as reported to the Food and Drug Administration medical device related web site. *J Vasc Interv Radiol* 2004;15:1185-92.
  18. Kim AK, Jensen ME, Dion JE, Schweickert PA, Kaufmann TJ, Kallmes DF. Unilateral transpedicular percutaneous vertebroplasty: Initial experience. *Radiology* 2002;222:737-41.
  19. Tohmeh AG, Mathis JM, Fenton DC, Levine AM, Belkoff SM. Biomechanical efficacy of unipedicular versus bipedicular vertebroplasty for the management of osteoporotic compression fractures. *Spine (Phila Pa 1976)* 1999;24:1772-6.
  20. Martin JB, Jean B, Sugiu K, San Millán Ruíz D, Piotin M, Murphy K, *et al.* Vertebroplasty: Clinical experience and followup results. *Bone* 1999;25:11S-5.
  21. Barr JD, Barr MS, Lemley TJ, McCann RM. Percutaneous vertebroplasty for pain relief and spinal stabilization. *Spine (Phila Pa 1976)* 2000;25:923-8.
  22. Padovani B, Kasriel O, Brunner P, Peretti-Viton P. Pulmonary embolism caused by acrylic cement: A rare complication of percutaneous vertebroplasty. *AJNR Am J Neuroradiol* 1999;20:375-7.
  23. Bandiera S, Gasbarrini A, De Iure F, Cappuccio M, Picci P, Boriani S. Symptomatic vertebral hemangioma: the treatment of 23 cases and a review of literature. *Chir Organi Mov* 2002;87:1-15.

**How to cite this article:** Narayana RV, Pati R, Dalai S. Percutaneous vertebroplasty in painful refractory vertebral hemangiomas. *Indian J Orthop* 2014;48:163-7.

**Source of Support:** Nil, **Conflict of Interest:** None.

### Author Help: Reference checking facility

The manuscript system ([www.journalonweb.com](http://www.journalonweb.com)) allows the authors to check and verify the accuracy and style of references. The tool checks the references with PubMed as per a predefined style. Authors are encouraged to use this facility, before submitting articles to the journal.

- The style as well as bibliographic elements should be 100% accurate, to help get the references verified from the system. Even a single spelling error or addition of issue number/month of publication will lead to an error when verifying the reference.
- Example of a correct style  
Sheahan P, O'leary G, Lee G, Fitzgibbon J. Cystic cervical metastases: Incidence and diagnosis using fine needle aspiration biopsy. *Otolaryngol Head Neck Surg* 2002;127:294-8.
- Only the references from journals indexed in PubMed will be checked.
- Enter each reference in new line, without a serial number.
- Add up to a maximum of 15 references at a time.
- If the reference is correct for its bibliographic elements and punctuations, it will be shown as CORRECT and a link to the correct article in PubMed will be given.
- If any of the bibliographic elements are missing, incorrect or extra (such as issue number), it will be shown as INCORRECT and link to possible articles in PubMed will be given.