

Case Report-I

Triple Negative Breast Cancer with Isolated Leptomeningeal Metastasis

SAMPATHKUMAR N.S, SAMBASIVAIAH K, NAGA SURESH M AND RAMAKRISHNA

ABSTRACT:

Isolated Leptomeningeal metastasis in breast cancer is rare. The diagnosis requires T1W MR scan of brain with gadolinium enhancement and demonstration of malignant cells in CSF. The treatment is palliative, which includes whole brain radiotherapy and chemotherapy.

INTRODUCTION

Distant metastasis to leptomeninges (LM) as the lone site of recurrence in breast cancer is rare. The molecular mechanisms responsible and predictive of such fatal development are unknown. The overall prognosis of such patients is generally poor, however few may have long-term survival. The management these patients is multifaceted and palliative nature. We report a case of triple negative, premenopausal breast cancer woman on follow up after adequate treatment, who developed only LM metastases.

CASE: 32 year-old premenopausal woman was treated for breast cancer (BC). She had lumpectomy with axillary dissection, followed by adjuvant radiation (RT) and 6 cycles of chemotherapy with FAC (5 Fluorouracil, adriamycin and cylophosphamide) regimen. The tumour characteristics included: histological grade III, pT 6 x 6 cm, pN 28 / 28 positive and estrogen receptor, progesterone receptor and HER2/neu were negative. She was on regular

follow up after completion of the treatment. Six months after completion of all tumour treatment, she presented to our out patient department with 20 days history of holocranial, intermittent, banding type headache with vomitings and blurring of vision in left eye. She also complained of diplopia. No history of fever, trauma and no other systemic symptoms.

Clinically the patient was drowsy but arousable to voice. When aroused, she was oriented to person, place and time. The cranial nerve examination was notable for bilateral papilloedema and decreased visual acuity (Right eye: 6/18; Left eye: 6/36). Motor strength was normal in upper and lower extremities. Reflexes were normal, with flexor plantar responses. Sensory system examination was normal. No signs of in coordination. Signs of meningeal irritation were present.

MRI T2W Brain plain was normal. MRI T1W Brain, with gadolinium contrast showed well defined areas of contrast enhancement along superior sagittal and straight sinuses and bilateral tentorial reflections

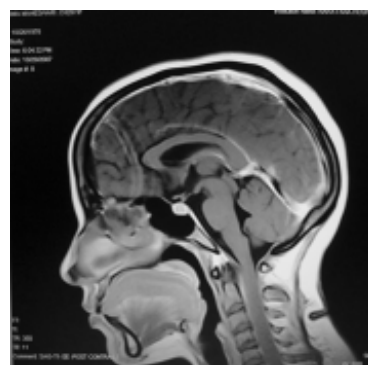

Figure1: MRI Brain, with gadolinium contrast showing well defined areas of contrast enhancement along superior sagittal and straight sinuses and bilateral tentorial reflections.

Department of Neurology (SampathKumar N.S and Naga Suresh M), Medical Oncology (Sambasivaiah K) and Pathology (Ramakrishna) Narayana Medical College Hospital, Nellore, Andhra Pradesh.
Correspondence to: **K.SAMBASIVAIAH**
Email: sambasvims@yahoo.co.in

CSF was under normal pressure and clear. Microscopic examination showed large, irregular glandular epithelial cells in attempted gland formation (Fig-2) There was lymphocytic

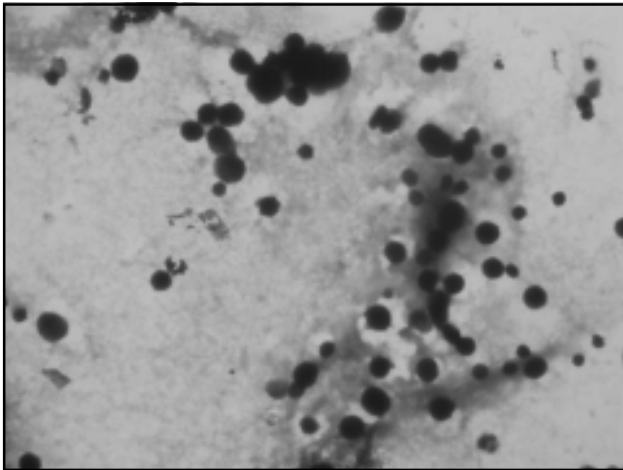


Figure-2: CSF examination showing large, irregular glandular epithelial cells in attempted gland formation

pleocytosis (65 cells/cu.mm- polymorphs33%; lymphocytes 67%) glucose- 35mg/dl; protein - 38mg/dl. Gram's, AFB, India Ink preparation and culture were negative. X-ray of the chest and ultrasound of liver did not reveal any metastases. Bone scan was normal. Hemogram, liver and renal function tests were normal. Patient responded to intravenous mannitol and dexamethasone. She was started on whole brain radiotherapy and palliative chemotherapy.

DISCUSSION

Early breast cancer carries an excellent prognosis following adequate local and adjuvant treatment. Certain prognostic factors are now established, e.g. hormone responsiveness, age, tumour size and number of axillary lymph nodes showing metastases. Long-term follow up is mandatory to diagnose relapses early. The most frequent sites of distant failures are bone, lung liver, brain and Leptomeningeal involvement in the context of metastatic disease in other sites is not uncommon. However, the metastasis to LM alone, is rare. This clinical situation raises relevance of blood brain barrier, in playing an

important role and affecting, however infrequent, the long-term survival for some of breast cancer patients. There is need to identify predictive factors for exclusive LM involvement, which might help devise an effective preventive strategy to further improve the success rates in breast cancer. It has been suggested that HER2/neu over expression may increase the risk of CNS metastases¹, however in this case HER2/neu was not over expressed. It is known that triple negative breast cancer carry a poor prognosis, but no data is available if this group has increased risk of LM metastases.

Diagnosis of Leptomeningeal metastases requires T1 W MRI scan of brain with gadolinium enhancement and CSF analysis demonstrating malignant cells. The other important issue for such patients is the treatment. They require multi modality treatment that includes whole brain radiotherapy and chemotherapy. Hormone responsive tumours should be given anti estrogen therapy, if necessary change of previous anti estrogen agent. Intrathecal chemotherapy has been tried. However, a randomized study in breast cancer patients with LM metastases, did not show any benefit in response or in survival, but was associated with substantial toxicities over non-intrathecal treatment.² The role of intravenous chemotherapy is not clear. Another observational study showed that both systemic and intrathecal chemotherapy as beneficial.³ There are few reports of oral capecitabine producing good responses and significant overall survival.⁴ Trastuzumab was reported to cross Blood brain barrier in patients with LM metastases.⁵ Few reports of successful use of Trastuzumab in breast cancer patients with LM metastases have been reported⁶. Trastuzumab may have a role, if the tumour has HER2/neu over expression. All treatment for such patients is palliative and Quality of life should be a top priority.

REFERENCES:

- 1) Kaal EC, Vecht CJ. CNS complications of breast cancer: current and emerging treatment options. *CNS Drugs*. 2007;21(7):559-79.
- 2) Boogerd W, van den Bent MJ, Koehler PJ, et al. The relevance of intraventricular chemotherapy for leptomeningeal metastasis in breast cancer: a randomised study. *Eur J Cancer*. 2004;40(18):2726-33.
- 3) Rudnicka H, Niwińska A, Murawska M. Breast cancer leptomeningeal metastasis—the role of multimodality treatment. *J Neurooncol*. 2007;84(1):57-62.
- 4) Tham YL, Hinckley L, Teh BS, Elledge R. Long-term clinical response in leptomeningeal metastases from breast cancer treated with capecitabine monotherapy: a case report. *Clin Breast Cancer*. 2006;7(2):164-6.
- 5) Carmona-Bayonas A. Concurrent radiotherapy and capecitabine, followed by high-dose methotrexate consolidation, provided effective palliation in a patient with Leptomeningeal metastases from breast cancer. *Ann Oncol*. 2007;18(1):199-200.
- 6) Stemmler HJ, Schmitt M, Harbeck N, et al. Application of intrathecal trastuzumab (Hercept-intrade mark) for treatment of meningeal carcinomatosis in HER2-overexpressing metastatic breast cancer. *Oncol Rep*. 2006;15(5):1373-7.

